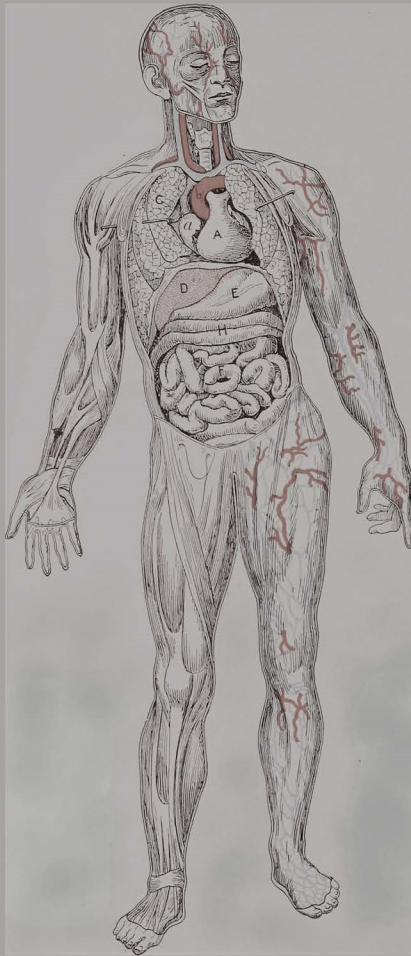


# Human Anatomy

## Self-Assessment Review Questions



Michael F. Nolan  
John P. McNamara

Virginia Tech Carilion School of Medicine

# Human Anatomy

# About this Book

This is an open textbook. That means that this book is freely available and you are welcome to use, adapt, and share it with attribution according to the Creative Commons Attribution International 4.0 license (CC BY 4.0).

Instructors and students reviewing, adopting, or adapting this textbook are encouraged to provide feedback (or report errors) online at: <https://bit.ly/feedback-human-anatomy>.

# Human Anatomy

## Self-Assessment Review Questions

Michael F. Nolan  
John P. McNamara

Virginia Tech Carilion School of Medicine  
in association with Virginia Tech Publishing  
Blacksburg, VA

A free version of this book can be downloaded from:  
<https://doi.org/10.21061/human-anatomy-self-assessment>

Copyright © 2022 by Michael F. Nolan and John P. McNamara

First published in 2022 by the Virginia Tech Carilion School of Medicine in association with Virginia Tech Publishing

Virginia Tech Carilion School of Medicine  
2 Riverside Circle  
Roanoke, VA 24016 USA

Virginia Tech Publishing  
University Libraries at Virginia Tech  
560 Drillfield Drive  
Blacksburg, VA 24061 USA



This work is licensed under the Creative Commons Attribution 4.0 International License. To view a copy of this license, visit <http://creativecommons.org/licenses/by/4.0/> or send a letter to Creative Commons, PO Box 1866, Mountain View, CA, 94042, USA. Note to users: This work may contain components (e.g., photographs, illustrations, or quotations) not covered by the license. Every effort has been made to identify these components but ultimately it is your responsibility to independently evaluate the copyright status of any work or component part of a work you use, in light of your intended use. Brand names, trademarks, and service marks in this book are legally protected and should not be used without prior authorization by their owners. Their inclusion in this book is for analytical, illustrative and pedagogical purposes only.

### **Cataloging-in-Publication Data**

Names: Nolan, Michael F., author | McNamara, John P., author.

Title: Human Anatomy: Self-Assessment Review Questions / Michael F. Nolan and John P. McNamara.

Description: Roanoke, VA : Virginia Tech Carilion School of Medicine in association with Virginia Tech Publishing, 2022. | Summary: "The anatomy questions included here are formatted in the short answer or fill in the blank style that requires the retrieval rather than the recognition of information; a format more closely aligned with that needed for everyday clinical practice. Each chapter includes a series of questions related to a particular area of anatomy. Answers to those questions are included at the end of the book." – Preface.

Identifiers: ISBN: 978-1-957213-30-9 (PDF) | ISBN: 978-1-957213-97-2 (pbk) |

DOI: <https://doi.org/10.21061/human-anatomy-self-assessment>

Subjects: HUMAN ANATOMY / Laboratory manuals. | HUMAN ANATOMY / Problems and Exercises.

# Table of Contents

Preface	vii
PART 1: Self-Assessment Questions	1
1 Back and Spine	3
2 Upper Limb	9
3 Lower Limb	21
4 Thoracic Wall	29
5 Pleura and Lungs	32
6 Mediastinum	35
7 Abdomen	41
8 Pelvis and Perineum	54
9 Head and Face	63
10 Mouth and Pharynx	76
11 Neck and Larynx	81
12 Orbit	95
13 Eye	99
14 Ear	103
PART 2: Answer Key	107
1 Back and Spine	108
2 Upper Limb	111
3 Lower Limb	117
4 Thoracic Wall	121
5 Pleura and Lungs	122
6 Mediastinum	124
7 Abdomen	127
8 Pelvis and Perineum	133
9 Head and Face	137
10 Mouth and Pharynx	143
11 Neck and Larynx	145
12 Orbit	152
13 Eye	154
14 Ear	156



# Preface

Human anatomy is one of the foundational disciplines in the training of health care professionals. Knowledge of human structure at both the macroscopic and microscopic levels serves as a framework for the study of normal function and dysfunction.

Resources used by students in their efforts to learn about human anatomy are exceptionally diverse in terms of scope, depth and focus as well as in the modalities and pedagogical approaches used. Diversity also exists in how knowledge acquisition is measured and evaluated.

Many students are familiar with formative and summative tests structured in the multiple-choice format. Most high stakes exams utilize this format and not surprisingly, numerous self-assessment resources are available to help students prepare for these types of examinations.

The self-assessment questions presented here are intended to help students in a different setting, a setting such as a ward, the clinic or the operating room where questions from teachers and preceptors are not likely to be presented as recognition exercises, that is, in the multiple-choice format, but rather as recall tasks. When information is obtained from patients in a teaching setting, it is not typical for a teacher to pose a question by asking “Which of the following five conditions does the patient have?” More likely the student will be asked to supply answer or explanation to an open-ended inquiry, such as, “What arteries do you think we will have to ligate in order to remove this inflamed appendix safely?” In this situation, the student will have to recall information or facts from previous experience or learning. Educators commonly describe this behavior as demonstrating knowledge by recall rather than recognition.

The anatomy questions included here are formatted in the short answer or fill in the blank style that requires the retrieval rather than the recognition of information; a format more closely aligned with that needed for everyday clinical practice.

Each chapter includes a series of questions related to a particular area of anatomy. Answers to those questions are included at the end of the book. It is our belief that this alternate approach to self-assessment in basic human anatomy will be helpful to students in preparing for clinical-based learning activities as well as for other types of knowledge assessment and evaluation.

MFN  
JPM





# Part 1: Self-Assessment Questions



# 1 Back and Spine

1. Indicate the number of vertebrae that comprise each region of the vertebral column.

- a. cervical \_\_\_\_\_
- b. thoracic \_\_\_\_\_
- c. lumbar \_\_\_\_\_
- d. sacral \_\_\_\_\_

2. Which two (2) regions of the vertebral column are characterized by curvatures in the sagittal plane with a concavity directed posteriorly?

- a. \_\_\_\_\_
- b. \_\_\_\_\_

3. Name each of the ligaments of the vertebral column described below.

- a. courses vertically along the anterior surfaces of adjacent vertebral bodies  
\_\_\_\_\_
- b. courses between adjacent laminae  
\_\_\_\_\_
- c. courses between adjacent spinous processes  
\_\_\_\_\_
- d. courses vertically along the posterior surfaces of adjacent vertebral bodies  
\_\_\_\_\_

4. What is the name of the thickened supraspinous ligament of the cervical spine?

\_\_\_\_\_

5. What is the name of the synovial joint formed by the superior and inferior articular processes of adjacent vertebrae?

---

6. Which group of vertebrae is characterized by transverse foraminae?

---

7. The carotid tubercle is an osteological feature of which vertebra?

---

8. The dens is an osteological feature of which vertebra?

---

9. Which vertebra is commonly referred to a “vertebra prominens”?

---

10. Name the two (2) parts of the vertebral arch.

a. \_\_\_\_\_

b. \_\_\_\_\_

11. What are the names of the two (2) parts of the intervertebral disc?

a. central fluid part \_\_\_\_\_

b. peripheral fibrous part \_\_\_\_\_

12. What is the name of the ligamentous structure that extends from the posterior arch of C1 (atlas) to the base of the cranium?

---

13. What is the name of the venous plexus located within the vertebral canal?

---

14. What is the name of the thickened connective tissue origin of the latissimus dorsi?

---

15. Name the three (3) muscles that form the borders of the triangle of auscultation.

a. \_\_\_\_\_

b. \_\_\_\_\_

c. \_\_\_\_\_

16. What two (2) muscles form the superficial layer of intrinsic back muscles?

a. \_\_\_\_\_

b. \_\_\_\_\_

17. What muscle group forms the intermediate layer of intrinsic back muscles?

---

18. What muscle group forms the deep layer of intrinsic back muscles?

---

19. What three (3) muscles form the suboccipital triangle?

a. \_\_\_\_\_

b. \_\_\_\_\_

c. \_\_\_\_\_

20. What two (2) structures lie in the floor of the suboccipital triangle?
- a. artery \_\_\_\_\_
  - b. nerve \_\_\_\_\_

21. Which spinal nerve gives rise to the greater occipital nerve?

\_\_\_\_\_

22. What vessel passes through the posterior atlanto-occipital membrane?

\_\_\_\_\_

23. In the adult, what vertebral level marks the caudal extent of the spinal cord?

\_\_\_\_\_

24. What is the name of the collection of dorsal and ventral roots that lie caudal to the tip of the spinal cord?

\_\_\_\_\_

25. What is the name of the pia matter structure that lies caudal to the tip of the spinal cord?

\_\_\_\_\_

26. What is the name of the CSF filled space located below the caudal tip of the spinal cord?

\_\_\_\_\_

27. What is the name of the meningeal structure that attaches to the dorsum of the coccyx?

\_\_\_\_\_

28. What is the name of the pia-derived structure that anchors the spinal cord to the lateral wall of the vertebral canal?

\_\_\_\_\_

29. What are the three (3) borders of the lumbar (Petit's) triangle?

a. \_\_\_\_\_

b. \_\_\_\_\_

c. \_\_\_\_\_

30. What part of the intervertebral disc is a remnant of the embryological notochord?

\_\_\_\_\_

31. What are the three (3) muscles that comprise the erector spinae (sacrospinalis) muscle group?

a. \_\_\_\_\_

b. \_\_\_\_\_

c. \_\_\_\_\_

32. What are the three (3) muscles that comprise the transversospinal group of the posterior spinal muscles?

a. \_\_\_\_\_

b. \_\_\_\_\_

c. \_\_\_\_\_



33. What are the four (4) components of the occipitoaxial ligament?

a. \_\_\_\_\_

b. \_\_\_\_\_

c. \_\_\_\_\_

d. \_\_\_\_\_

34. What nerve innervates the muscles of the suboccipital triangle?

\_\_\_\_\_

35. What is the name of the lower sacral segments of the spinal cord?

\_\_\_\_\_

36. What vertebral segment marks the caudal extent of the spinal subarachnoid space?

\_\_\_\_\_

# 2 Upper Limb

1. Name the two (2) parts of the clavipectoral fascia.
  - a. \_\_\_\_\_
  - b. \_\_\_\_\_
  
2. What vein lies in the deltopectoral groove?  
\_\_\_\_\_
  
3. What vein passes through the costocoracoid membrane?  
\_\_\_\_\_
  
4. What spinal segment (spinal nerve) provides sensory innervation to each of the following digits?
  - a. palmar surface of the little finger \_\_\_\_\_
  - b. palmar surface of the thumb \_\_\_\_\_
  - c. palmar surface of the long finger \_\_\_\_\_
  
5. What veins lie in the subcutaneous tissue of the medial surface of the forearm?  
\_\_\_\_\_
  
6. What vein serves as an anastomosis between the cephalic vein and the basilic vein?  
\_\_\_\_\_

7. What nerve continues into the forearm as the lateral antebrachial cutaneous nerve?

---

8. What anatomical landmark marks the point where the axillary artery becomes the brachial artery?

---

9. What landmarks are used to divide the axillary artery into three (3) parts?

---

10. Name the major branches of the axillary artery:

a. first part 

---

b. second part 

---

c. third part 

---

---

---

11. What is the insertion of the pectoralis minor?

---

12. What is the insertion of the pectoralis major?

---

13. What is the insertion of the serratus anterior?

---

14. What is the insertion of the trapezius?

---

15. What is the insertion of the latissimus dorsi?

---

16. What is the insertion of the subscapularis?

---

17. What is the insertion of the deltoid?

---

18. Which of the “rotator cuff” muscles is NOT an external rotator of the glenohumeral joint?

---

19. What muscle forms the medial wall of the axilla?

---

20. What anatomical feature marks the lateral wall of the axilla?

---

21. What anatomical landmark marks the point where the subclavian artery becomes the axillary artery?

---

22. What four (4) muscles form the borders of the quadrangular space?
- a. \_\_\_\_\_
  - b. \_\_\_\_\_
  - c. \_\_\_\_\_
  - d. \_\_\_\_\_
23. What two (2) structures pass through the quadrangular space?
- a. \_\_\_\_\_
  - b. \_\_\_\_\_
24. What nerve lies in the intermuscular fascia separating the biceps brachii and the brachialis?
- \_\_\_\_\_
25. What nerve innervates the muscles of the posterior compartment of the arm?
- \_\_\_\_\_
26. What nerve crosses the elbow joint on the deep surface of the brachioradialis?
- \_\_\_\_\_
27. What are the two (2) terminal branches of the brachial artery?
- a. \_\_\_\_\_
  - b. \_\_\_\_\_
28. What is the bony insertion of the biceps brachii?
- \_\_\_\_\_

29. What is the insertion of the brachialis?

---

30. What vein lies superficial to the bicipital aponeurosis?

---

31. What muscles form the medial and lateral borders of the cubital fossa?

a. medial border \_\_\_\_\_

b. lateral border \_\_\_\_\_

32. What two (2) muscles form the floor of the cubital fossa?

a. \_\_\_\_\_

b. \_\_\_\_\_

33. What nerve enters the forearm, passing posterior to the medial epicondyle?

---

34. What are the four (4) muscles that form the superficial layer of the anterior compartment of the forearm?

a. \_\_\_\_\_

b. \_\_\_\_\_

c. \_\_\_\_\_

d. \_\_\_\_\_

35. What muscle forms the intermediate layer of the anterior compartment of the forearm?

---

36. What three (3) muscles form the deep layer of the anterior compartment of the forearm?

a. \_\_\_\_\_

b. \_\_\_\_\_

c. \_\_\_\_\_

37. Which one (1) of the muscles of the anterior compartment is NOT innervated by the median nerve?

\_\_\_\_\_

38. Which of the muscles of the anterior compartment of the forearm has a tendon that passes superficial to the flexor retinaculum?

\_\_\_\_\_

39. Which of the muscles of the anterior compartment of the forearm receives motor innervation by way of two different peripheral nerves?

\_\_\_\_\_

40. Which two (2) muscles of the posterior compartment of the forearm do NOT have tendons that cross the wrist joint?

a. \_\_\_\_\_

b. \_\_\_\_\_

41. What nerve innervates muscles that extend the wrist?

\_\_\_\_\_

42. What three (3) muscles form the hypothenar eminence?

a. \_\_\_\_\_

b. \_\_\_\_\_

c. \_\_\_\_\_

43. What four (4) muscles form the thenar eminence?

a. \_\_\_\_\_

b. \_\_\_\_\_

c. \_\_\_\_\_

d. \_\_\_\_\_

44. Which of the thenar muscles is innervated by both the median nerve and the ulnar nerves?

\_\_\_\_\_

45. Which of the intrinsic muscles of the hand adduct the medial four fingers?

\_\_\_\_\_

46. Which of the intrinsic muscles of the hand abduct the medial four fingers?

\_\_\_\_\_

47. What nerve enters the hand by passing through Guyon's canal?

\_\_\_\_\_

48. What branch of the ulnar nerve provides sensory innervation to the skin over the palmar surface of the little finger?

\_\_\_\_\_



49. What is the name of the fibrocartilaginous structure that “deepens” the glenohumeral joint?

---

50. What are the two (2) parts of the coracoclavicular ligament?

a. \_\_\_\_\_

b. \_\_\_\_\_

51. Which ligament of the shoulder does NOT cross the glenohumeral joint?

---

52. Name the bones that form the proximal row of carpal bones.

a. \_\_\_\_\_

b. \_\_\_\_\_

c. \_\_\_\_\_

d. \_\_\_\_\_

53. Name the bones that form the distal row of carpal bones.

a. \_\_\_\_\_

b. \_\_\_\_\_

c. \_\_\_\_\_

d. \_\_\_\_\_

54. What two (2) structures pass through the triangular interval?

a. \_\_\_\_\_

b. \_\_\_\_\_

55. What artery passes through the triangular space?  
\_\_\_\_\_
56. What muscle forms the medial border of the 'anatomical snuff box'?  
\_\_\_\_\_
57. What arterial pulse can be palpated in the "anatomical snuff box"?  
\_\_\_\_\_
58. Which of the carpal bones can be palpated in the floor of the "anatomical snuff box"?  
\_\_\_\_\_
59. Which joint of the hand lies immediately deep to the extensor hood (extensor expansion)?  
\_\_\_\_\_
60. What is the action of the lumbrical muscle on each of the following joints of the finger?
- a. MP \_\_\_\_\_
  - b. PIP \_\_\_\_\_
  - c. DIP \_\_\_\_\_
61. Which two heads of the triceps brachii originate from the humerus?
- a. \_\_\_\_\_
  - b. \_\_\_\_\_
62. What artery gives rise to the common interosseous artery?  
\_\_\_\_\_

63. What artery supplies the deep muscles of the posterior forearm?  
\_\_\_\_\_

64. What two arteries form an anastomotic connection behind the medial epicondyle?  
a. \_\_\_\_\_  
b. \_\_\_\_\_

65. What two arteries form an anastomotic connection in front of the medial epicondyle?  
a. \_\_\_\_\_  
b. \_\_\_\_\_

66. What two arteries form an anastomotic connection behind the lateral epicondyle?  
a. \_\_\_\_\_  
b. \_\_\_\_\_

67. What two arteries form an anastomotic connection in front of the lateral epicondyle?  
a. \_\_\_\_\_  
b. \_\_\_\_\_

68. Describe the fiber orientation (direction) of the interosseous membrane.  
\_\_\_\_\_

69. What bone is found in the floor of the “anatomical snuff box”?  
\_\_\_\_\_

70. What are the branches of the brachial artery not including its terminal branches?
- a. \_\_\_\_\_
  - b. \_\_\_\_\_
  - c. \_\_\_\_\_
71. What are the major terminal branches of the profunda brachial artery?
- a. \_\_\_\_\_
  - b. \_\_\_\_\_
  - c. \_\_\_\_\_
72. What nerve passes through the scapular notch (beneath the transverse scapular ligament)?
- \_\_\_\_\_
73. What muscle inserts on the lesser tuberosity of the humerus?
- \_\_\_\_\_
74. On which bone of the forearm does the tendon of the biceps brachii insert?
- \_\_\_\_\_
75. On which bone of the forearm does the tendon of the brachialis insert?
- \_\_\_\_\_
76. Which two (2) carpal bones form the radiocarpal joint?
- a. \_\_\_\_\_
  - b. \_\_\_\_\_

77. What spinal nerve roots contribute to form the long thoracic nerve?

---

78. Excluding the terminal branches, what three (3) nerves are branches of the posterior cord of the brachial plexus?

a. \_\_\_\_\_

b. \_\_\_\_\_

c. \_\_\_\_\_

79. Which of the thenar muscles is NOT innervated by the median nerve?

---

80. The ulnar nerve passes into the forearm, passing between the two heads of origin of what muscle?

---

81. The median nerve passes into the forearm, passing between the two heads of origin of what muscle?

---

82. The radial nerve passes into the forearm, passing between the two heads of origin of what muscle?

---

# 3 Lower Limb

1. What two (2) bones form the pelvic girdle?

a. \_\_\_\_\_

b. \_\_\_\_\_

2. What three (3) bones form the hip bone (os coxae or innominate bone)?

a. \_\_\_\_\_

b. \_\_\_\_\_

c. \_\_\_\_\_

3. What are the two attachments of the inguinal ligament?

a. lateral attachment \_\_\_\_\_

b. medial attachment \_\_\_\_\_

4. What is the numerical value of the angle of inclination in the adult?

\_\_\_\_\_

5. What is the numerical value of the angle of declination (torsion) in the adult?

\_\_\_\_\_

6. What is the name of the deep fascia of the thigh?

\_\_\_\_\_

7. What is the name of the thickened part of the deep fascia on the lateral surface of the thigh?

---

8. What is the name of the thin fascial layer that covers the saphenous opening of the fascia lata?

---

9. Into what vein does the great saphenous vein drain?

---

10. Into what vein does the small saphenous vein drain?

---

11. What spinal segments give rise to nerve fibers that form the femoral nerve?

---

12. What spinal segments give rise to nerve fibers that form the obturator nerve?

---

13. What peripheral nerve provides sensory innervation to the skin on the dorsal surface of the foot between the 1st and 2nd metatarsals?

---

14. What is the origin of the sartorius?

---

15. What is the origin of the rectus femoris?  
\_\_\_\_\_
16. What is the insertion of the psoas major?  
\_\_\_\_\_
17. The adductor hiatus is an opening in the aponeurotic attachment of what muscle?  
\_\_\_\_\_
18. What structure passes through the adductor hiatus?  
\_\_\_\_\_
19. What are the borders of the femoral triangle?  
a. superior \_\_\_\_\_  
b. medial \_\_\_\_\_  
c. lateral \_\_\_\_\_
20. List from lateral to medial, the three (3) neurovascular structures that course through the femoral triangle.  
a. \_\_\_\_\_  
b. \_\_\_\_\_  
c. \_\_\_\_\_
21. Is the femoral canal located (medial / lateral) to the neurovascular structures of the femoral triangle?  
\_\_\_\_\_
22. What is located in the femoral canal?  
\_\_\_\_\_



23. Which of the structures passing deep to the inguinal ligament is NOT enclosed in the femoral sheath?

\_\_\_\_\_

24. What is the terminal branch of the femoral nerve?

\_\_\_\_\_

25. In addition to the femoral nerve, what other nerve passes deep to the inguinal ligament to reach the thigh?

\_\_\_\_\_

26. What nerve provides motor innervation to the adductor muscles of the thigh?

\_\_\_\_\_

27. What is the major artery that supplies the structures of the thigh?

\_\_\_\_\_

28. What is the insertion of the gluteus medius?

\_\_\_\_\_

29. What three (3) muscles insert as the pes anserinus?

a. \_\_\_\_\_

b. \_\_\_\_\_

c. \_\_\_\_\_

30. Name the nerve that innervates each of the two heads of the biceps femoris.

a. long head \_\_\_\_\_

b. short head \_\_\_\_\_

31. The sciatic nerve passes through the gluteal region by passing either under, over, or through what muscle?

---

32. What nerve lies in the floor of the popliteal fossa?

---

33. Name the cutaneous nerve of the posterior surface of the leg.

---

34. What nerve lies immediately posterior to the head of the fibula?

---

35. Name the four (4) muscles of the anterior compartment of the leg.

a. 

---

b. 

---

c. 

---

d. 

---

36. What nerve provides motor innervation to the muscles of the anterior compartment of the leg?

---

37. Name the three (3) muscles of the superficial layer of the posterior compartment of the leg.

a. 

---

b. 

---

c. 

---

38. Name the four (4) muscles of the deep layer of the posterior compartment of the leg.

a. \_\_\_\_\_

b. \_\_\_\_\_

c. \_\_\_\_\_

d. \_\_\_\_\_

39. The pulse of what artery can be palpated on the dorsal surface of the foot?

\_\_\_\_\_

40. What are the two (2) actions at the ankle of the muscles of the lateral compartment of the leg?

a. \_\_\_\_\_

b. \_\_\_\_\_

41. What nerve provides sensory innervation to the skin over the lateral surface of the 5th metatarsal?

\_\_\_\_\_

42. Which two (2) muscles of the leg exert an action on the knee joint?

a. \_\_\_\_\_

b. \_\_\_\_\_

43. What is the insertion of the gastrocnemius?

\_\_\_\_\_

44. What nerve provides sensory innervation to the skin over the anterior compartment of the leg?

\_\_\_\_\_

45. What nerve of the leg terminates as the medial and lateral plantar nerves of the foot?

---

46. Name the three (3) ligaments that reinforce the stability of the hip joint.

a. \_\_\_\_\_

b. \_\_\_\_\_

c. \_\_\_\_\_

47. What artery gives rise to the artery of the head of the femur?

---

48. What artery is the usual origin of the anterior and posterior femoral circumflex arteries?

---

49. What ligament of the knee resists posterior displacement of the tibia on the femur?

---

50. What ligament of the ankle joint is commonly referred to as the deltoid ligament?

---

51. The pulse of what artery can be palpated on the posterior to the medial malleolus?

---

52. What are the six (6) main branches of the femoral artery in the femoral triangle?

a. \_\_\_\_\_

b. \_\_\_\_\_

c. \_\_\_\_\_

d. \_\_\_\_\_

e. \_\_\_\_\_

f. \_\_\_\_\_

# 4 Thoracic Wall

1. Name the three (3) parts of the sternum.

a. \_\_\_\_\_

b. \_\_\_\_\_

c. \_\_\_\_\_

2. Which rib attaches anteriorly at the level of the sternal angle (angle of Louis)?

\_\_\_\_\_

3. Which ribs are defined as vertebra-sternal ribs?

\_\_\_\_\_

4. At rest, what vertebral body would be crossed by a horizontal line extending posteriorly from the xiphisternal joint?

\_\_\_\_\_

5. Which spinal nerve provides sensory innervation to the skin of the nipple?

\_\_\_\_\_

6. In the midaxillary line, the intercostal vessels and nerves are located between which two intercostal muscles?

a. \_\_\_\_\_

b. \_\_\_\_\_

7. Name the artery that is the origin of each of the arteries listed below.

	Artery	Origin
a.	anterior intercostal art.	_____
b.	posterior intercostal art.	_____

8. Which set of posterior intercostal arteries (left or right) passes laterally, across the vertebral body to reach the intercostal space?

\_\_\_\_\_

9. The intercostal vessels and nerve lie in the costal groove. What is the order of these structures from superior to inferior?

- a. \_\_\_\_\_
- b. \_\_\_\_\_
- c. \_\_\_\_\_

10. What is the action of each of the muscles listed below?

	Muscle	Action
a.	serratus posterior inferior	_____
b.	serratus posterior superior	_____

11. The female breast receives its arterial blood supply by way of the medial and lateral mammary arteries. What is the origin of each of these two sets of vessels?

	Artery	Origin
a.	lateral mammary art	_____
b.	medial mammary art	_____

12. What are the two (2) terminal branches of the internal thoracic artery?
- a. \_\_\_\_\_
- b. \_\_\_\_\_
13. At rest, what vertebral body would be crossed by a horizontal line extending posteriorly from the sternal angle?
- \_\_\_\_\_
14. Which costal cartilage marks the point where the internal thoracic artery divides into its two (2) terminal branches?
- \_\_\_\_\_



# 5 Pleura and Lungs

1. Name the four (4) parts of the parietal pleura.

a. \_\_\_\_\_

b. \_\_\_\_\_

c. \_\_\_\_\_

d. \_\_\_\_\_

2. What structure passes over the top of the hilum of the lung on the right side?

\_\_\_\_\_

3. What structure passes over the top of the hilum of the lung on the left side?

\_\_\_\_\_

4. What is the name of the pleural structure that extends inferiorly from the root of the lung to the diaphragm?

\_\_\_\_\_

5. At what vertebral level does the trachea divide into main stem bronchi?

\_\_\_\_\_

6. Into what vessel do each of the following veins drain into?

Vein	Receiving Vein
a. left bronchial vein	_____

b. right bronchial vein	_____
-------------------------	-------

7. Which main stem bronchus is wider?  
\_\_\_\_\_
8. Indicate the rib overlying the pleural reflection in the:
- a. midclavicular line \_\_\_\_\_
  - b. midaxillary line \_\_\_\_\_
  - c. midscapular line \_\_\_\_\_
9. Which costal cartilage marks the point where the pleural reflection moves laterally beneath the body of the sternum on the right side?  
\_\_\_\_\_
10. Which costal cartilage marks the point where the pleural reflection moves laterally beneath the body of the sternum on the right side?  
\_\_\_\_\_
11. Which rib overlies the lung boundary in the:
- a. midclavicular line \_\_\_\_\_
  - b. midaxillary line \_\_\_\_\_
  - c. midscapular line \_\_\_\_\_
12. Which costal cartilage marks the point where the medial edge of the right lung moves laterally beneath the body of the sternum?  
\_\_\_\_\_
13. Which costal cartilage marks the point where the medial edge of the left lung moves laterally beneath the body of the sternum?  
\_\_\_\_\_

14. The oblique fissure lies parallel to a line connecting the:
- a. \_\_\_\_\_ spinous process posteriorly
  - b. \_\_\_\_\_ rib in the midaxillary line
  - c. \_\_\_\_\_ costal cartilage anteriorly
15. The horizontal fissure lies parallel to a line interconnecting the:
- a. \_\_\_\_\_ in the midaxillary line laterally
  - b. \_\_\_\_\_ costal cartilage anteriorly
16. What spinal cord segments give rise to the phrenic nerve?
- \_\_\_\_\_
17. Which lobe of the lung is aerated by the eparterial bronchus?
- \_\_\_\_\_
18. In the root of the neck, the phrenic nerve lies on the anterior surface of what muscle?
- \_\_\_\_\_
19. The phrenic nerve lies (anterior / posterior) to the root of the lung as it descends toward the diaphragm?
- \_\_\_\_\_
20. What vessels accompany the phrenic nerve as it passes the root of the lung?
- \_\_\_\_\_

# 6 Mediastinum

1. The boundary between the superior mediastinum and the inferior mediastinum can be described as a horizontal line extending from the:

a. \_\_\_\_\_ anteriorly

b. \_\_\_\_\_ posteriorly

2. Name the four (4) major branches of the left coronary artery.

a. \_\_\_\_\_

b. \_\_\_\_\_

c. \_\_\_\_\_

d. \_\_\_\_\_

3. Name the four (4) major branches of the right coronary artery.

a. \_\_\_\_\_

b. \_\_\_\_\_

c. \_\_\_\_\_

d. \_\_\_\_\_

4. Which cardiac valve is located between the right atrium and right ventricle?

\_\_\_\_\_

5. Indicate the location of the nerve cells that provide autonomic innervation to the heart.
- a. preganglionic sympathetic \_\_\_\_\_
  - b. postganglionic sympathetic \_\_\_\_\_
  - c. preganglionic parasympathetic \_\_\_\_\_
  - d. postganglionic parasympathetic \_\_\_\_\_
6. Name in order from proximal to distal, the three (3) arteries that arise from the arch of the aorta.
- a. \_\_\_\_\_
  - b. \_\_\_\_\_
  - c. \_\_\_\_\_
7. The azygos vein drains into what vein?
- \_\_\_\_\_
8. Pectinate muscles are a feature of which chamber of the heart?
- \_\_\_\_\_
9. Which artery passes horizontally, immediately posterior to the ascending aorta (be specific)?
- \_\_\_\_\_
10. Which cardiac veins do NOT drain into the coronary sinus?
- \_\_\_\_\_
11. In the superior mediastinum, what structure lies immediately posterior to the trachea?
- \_\_\_\_\_

12. The thoracic duct drains into the angle formed by which two vessels?
- a. \_\_\_\_\_
- b. \_\_\_\_\_
13. In the superior mediastinum, the left phrenic nerve lies (anterior / posterior) to the left pulmonary artery.
- \_\_\_\_\_
14. In the superior mediastinum, the left brachiocephalic vein lies (anterior / posterior) to the left common carotid artery.
- \_\_\_\_\_
15. In the superior mediastinum, the ascending aorta lies (anterior / posterior) to the trachea.
- \_\_\_\_\_
16. In the superior mediastinum, the esophagus lies (anterior / posterior) to the trachea.
- \_\_\_\_\_
17. In the superior mediastinum, the thoracic duct lies (anterior / posterior) to the superior vena cava.
- \_\_\_\_\_
18. In the superior mediastinum, the descending aorta lies (anterior / posterior) to the left main stem bronchus.
- \_\_\_\_\_

19. In the superior mediastinum, the descending aorta lies (anterior / posterior) to the left pulmonary artery.

---

20. In the posterior mediastinum, the thoracic duct lies (to the right / to the left) of the thoracic aorta.

---

21. In the posterior mediastinum, the esophagus lies (anterior / posterior) to the descending aorta.

---

22. What is the origin of the internal thoracic artery?

---

23. Name the opening in the respiratory diaphragm does NOT open into the posterior mediastinum?

---

24. The phrenic nerve courses inferiorly through the mediastinum, passing \_\_\_\_\_ (anterior or posterior) to the root of the lung.

25. The vagus nerve courses inferiorly through the mediastinum, passing \_\_\_\_\_ (anterior or posterior) to the root of the lung.

26. What vertebral level marks each of the following openings in the diaphragm?

	Opening	Vertebral level
a.	aortic hiatus	_____
b.	vena caval hiatus	_____
c.	esophageal hiatus	_____

27. Where is the best place on the chest to auscultate the aortic valve?

\_\_\_\_\_

28. Where is the best place on the chest to auscultate the tricuspid valve?

\_\_\_\_\_

29. Where is the best place on the chest to auscultate the pulmonary valve?

\_\_\_\_\_

30. Where is the best place on the chest to auscultate the mitral valve?

\_\_\_\_\_

31. Which covering of the heart is also known as the epicardium?

\_\_\_\_\_

32. Which chamber forms the right border of the heart?

\_\_\_\_\_

33. Which coronary artery gives rise to a branch that supplies the SA node?

\_\_\_\_\_



34. What structure lies immediately behind the esophagus at the T10 vertebral level?

---

35. What structure lies on the anterior surface of the left main stem bronchus?

---

# 7 Abdomen

1. Name the layer of fascia located immediately deep to the transversus abdominus muscle.

---

2. What structure forms the posterior wall of the rectus sheath above the arcuate line?

---

3. Name two (2) arteries that perfuse the anterior abdominal wall, that originate from the external iliac artery?

a. 

---

b. 

---

4. Name two (2) arteries that perfuse the anterior abdominal wall that originate from the femoral artery?

a. 

---

b. 

---

5. What artery forms an anastomotic connection with the inferior epigastric artery?

---

6. What spinal nerve provides sensory innervation to the skin of the umbilicus?

---

7. What artery supplies the rectus abdominus muscle at the level of the arcuate line?

\_\_\_\_\_

8. Name the attachments of the inguinal ligament.

a. superolateral \_\_\_\_\_

b. inferomedial \_\_\_\_\_

9. What structure forms the deep inguinal ring?

\_\_\_\_\_

10. What structure forms the superficial inguinal ring?

\_\_\_\_\_

11. The femoral nerve, artery and vein enter the thigh by coursing deep to the inguinal ligament. What is the anatomical relationship of these three structures, from medial to lateral?

a. \_\_\_\_\_

b. \_\_\_\_\_

c. \_\_\_\_\_

12. What structure contributes to each of the three (3) layers of the spermatic cord?

a. external spermatic fascia \_\_\_\_\_

b. cremaster fascia \_\_\_\_\_

c. internal spermatic fascia \_\_\_\_\_

13. Which of the abdominal muscles gives rise to the cremaster muscle?

\_\_\_\_\_

14. What nerve provides motor innervation to the cremaster muscle?  
\_\_\_\_\_
15. Name the tubular structure associated with the testes where sperm cells are stored until ejaculation.  
\_\_\_\_\_
16. What structure of the abdomen gives rise to the tunica vaginalis of the testes?  
\_\_\_\_\_
17. Into what veins do the right and left testicular veins drain?
- a. right testicular vein \_\_\_\_\_
  - b. left testicular vein \_\_\_\_\_
18. Name the three (3) parts of the greater omentum.
- a. \_\_\_\_\_
  - b. \_\_\_\_\_
  - c. \_\_\_\_\_
19. Name the two (2) parts of the lesser omentum.
- a. \_\_\_\_\_
  - b. \_\_\_\_\_
20. What three (3) structures are located within the hepatoduodenal ligament?
- a. \_\_\_\_\_
  - b. \_\_\_\_\_
  - c. \_\_\_\_\_

21. The muscular wall of the esophagus is formed by both smooth and striated muscle. Indicate the type of muscle that is found in each of the three (3) regions of the esophagus listed below.

a. proximal 1/3 \_\_\_\_\_

b. middle 1/3 \_\_\_\_\_

c. distal 1/3 \_\_\_\_\_

22. What nerve provides motor innervation to each of the three (3) regions of the esophagus?

a. proximal 1/3 \_\_\_\_\_

b. middle 1/3 \_\_\_\_\_

c. distal 1/3 \_\_\_\_\_

23. Name the four (4) parts (regions) of the stomach.

a. \_\_\_\_\_

b. \_\_\_\_\_

c. \_\_\_\_\_

d. \_\_\_\_\_

24. What arterial branch of the aorta gives rise to branches that supply the stomach?

\_\_\_\_\_

25. What arteries form the anastomotic network located on the lesser curvature of the stomach AND what is the origin of each of these arteries?

Artery

Origin

a. \_\_\_\_\_

b. \_\_\_\_\_

26. What arteries form the anastomotic network located on the greater curvature of the stomach AND what is the origin of each of these arteries?

	Artery	Origin
a.	_____	_____
b.	_____	_____

27. Name the three (3) major branches of the celiac trunk.

- a. \_\_\_\_\_
- b. \_\_\_\_\_
- c. \_\_\_\_\_

28. Name the three (3) branches of the common hepatic artery.

- a. \_\_\_\_\_
- b. \_\_\_\_\_
- c. \_\_\_\_\_

29. Name the two (2) branches of the gastroduodenal artery.

- a. \_\_\_\_\_
- b. \_\_\_\_\_

30. Name the two (2) veins that drain into the portal vein.

- a. \_\_\_\_\_
- b. \_\_\_\_\_

31. What two (2) structures form the common bile duct?

- a. \_\_\_\_\_
- b. \_\_\_\_\_

32. What two (2) structures drain into the hepatopancreatic ampulla (ampulla of Vater)?

a. \_\_\_\_\_

b. \_\_\_\_\_

33. Into which part of the duodenum does the hepatopancreatic ampulla drain?

\_\_\_\_\_

34. What structure marks the point where the hepatoduodenal papilla enters the duodenum?

\_\_\_\_\_

35. What structure drains into the duodenum by way of the minor duodenal papilla?

\_\_\_\_\_

36. At what level of the vertebral column does the horizontal part (3rd part) of the duodenum cross the vertebral column?

\_\_\_\_\_

37. What artery lies immediately anterior to the horizontal part of the duodenum?

\_\_\_\_\_

38. What structure “supports/suspends” the small intestine at the level of the duodenal-jejunal junction?

\_\_\_\_\_

39. Which parts of the duodenum are considered to be retroperitoneal?  
\_\_\_\_\_
40. Which parts of the duodenum are supplied by branches of the celiac artery?  
\_\_\_\_\_
41. The superior mesenteric artery supplies arterial blood to the intestine. Indicate the proximal most part and the distal most part of the intestine that receives arterial blood supply by way of branches of the superior mesenteric artery.
- a. proximal most part \_\_\_\_\_
- b. distal most part \_\_\_\_\_
42. What part(s) of the intestine receive arterial blood supply by way of branches of the inferior mesenteric artery?  
\_\_\_\_\_
43. What part(s) of the intestine are drained by branches of the inferior mesenteric vein?  
\_\_\_\_\_
44. Which parts of the colon are retroperitoneal?  
\_\_\_\_\_
45. What three (3) structures form the portal triad?
- a. \_\_\_\_\_
- b. \_\_\_\_\_
- c. \_\_\_\_\_



46. What structure divides the liver into left and right lobes?

---

47. Which two (2) lobes of the liver lie on either side of the porta hepatis?

a. \_\_\_\_\_

b. \_\_\_\_\_

48. The round ligament (ligamentum teres) of the liver is a remnant of what embryological structure?

---

49. The ligamentum venosum of the liver is the remnant of what embryological structure?

---

50. In its course to the right kidney, the right renal artery passes (anterior / posterior) to the inferior vena cava.

---

51. In its course from the left kidney to the inferior vena cava, the left renal vein passes (anterior / posterior) to the aorta.

---

52. Indicate the origin of each of the suprarenal arteries listed below.

	Suprarenal art.	Origin
a.	superior suprarenal art.	_____
b.	middle suprarenal art.	_____
c.	inferior suprarenal art.	_____

53. Which spinal cord segments are the origin of the greater splanchnic nerve?  
\_\_\_\_\_
54. Which spinal cord segments are the origin of the lesser splanchnic nerve?  
\_\_\_\_\_
55. Name the structure that forms the lateral umbilical fold.  
\_\_\_\_\_
56. Name the structure that forms the medial umbilical fold.  
\_\_\_\_\_
57. At what vertebral level does the aorta bifurcate to form the common iliac arteries?  
\_\_\_\_\_
58. At what vertebral level do the common iliac veins join to form the inferior vena cava?  
\_\_\_\_\_
59. What are the five (5) branches of the superior mesenteric artery?  
a. \_\_\_\_\_  
b. \_\_\_\_\_  
c. \_\_\_\_\_  
d. \_\_\_\_\_  
e. \_\_\_\_\_

60. What are the three (3) branches of the inferior mesenteric artery?
- a. \_\_\_\_\_
  - b. \_\_\_\_\_
  - c. \_\_\_\_\_
61. What paired lymphatic structures drain into the cisterna chyli?
- \_\_\_\_\_
62. What two (2) nerves lie in the inguinal canal?
- a. \_\_\_\_\_
  - b. \_\_\_\_\_
63. Are the tendinous intersections of the abdominal wall located above or below the arcuate line?
- \_\_\_\_\_
64. Name the plexus of nerves that lies on the anterior surface of the bifurcation of the aorta.
- \_\_\_\_\_
65. What section of the small intestine is associated with Meckel's diverticulum?
- \_\_\_\_\_
66. What are the three (3) parts of the teniae coli?
- a. \_\_\_\_\_
  - b. \_\_\_\_\_
  - c. \_\_\_\_\_

67. What nerve lies on the anterior surface of the psoas major muscle?  
\_\_\_\_\_

68. What are the two (2) components of the superficial layer of abdominal fascia?  
a. \_\_\_\_\_  
b. \_\_\_\_\_

69. What component of the spermatic cord is formed by the deep fascia of the abdomen?  
\_\_\_\_\_

70. What component of the penis is formed by the deep fascia of the abdomen?  
\_\_\_\_\_

71. What are the eight (8) branches of the lumbar plexus?  
a. \_\_\_\_\_  
b. \_\_\_\_\_  
c. \_\_\_\_\_  
d. \_\_\_\_\_  
e. \_\_\_\_\_  
f. \_\_\_\_\_  
g. \_\_\_\_\_  
h. \_\_\_\_\_

72. Name the tributaries of the inferior vena cava.

- a. \_\_\_\_\_
- b. \_\_\_\_\_
- c. \_\_\_\_\_
- d. \_\_\_\_\_
- e. \_\_\_\_\_
- f. \_\_\_\_\_

73. Name the origin of each of the arteries listed below that perfuse the stomach.

Gastric Vessel	Origin
a. short gastric artery	_____
b. left gastric artery	_____
c. right gastric artery	_____
d. left gastroepiploic artery	_____
e. right gastroepiploic artery	_____

74. Name the muscles that pass beneath the medial and lateral arcuate ligaments of the respiratory diaphragm.

- a. medial arcuate ligament \_\_\_\_\_
- b. lateral arcuate ligament \_\_\_\_\_

75. Name the three (3) abdominal organs with veins that drain into the splenic vein.

- a. \_\_\_\_\_
- b. \_\_\_\_\_
- c. \_\_\_\_\_

76. Name the three (3) borders of the lumbar triangle.

a. \_\_\_\_\_

b. \_\_\_\_\_

c. \_\_\_\_\_

77. Name the three (3) borders of the inguinal triangle.

a. \_\_\_\_\_

b. \_\_\_\_\_

c. \_\_\_\_\_

78. What embryonic structure is located in the free margin of the falciform ligament?

\_\_\_\_\_

# 8 Pelvis and Perineum

1. Name the three (3) bones that form the “hip” bone (coxal bone).

a. \_\_\_\_\_

b. \_\_\_\_\_

c. \_\_\_\_\_

2. Which part of the pelvis is located above (superior to) the pelvic brim?

\_\_\_\_\_

3. What ligament converts the sciatic notch into the sciatic foramen?

\_\_\_\_\_

4. What ligament subdivides the sciatic foramen into the greater and lesser sciatic foraminae?

\_\_\_\_\_

5. What two (2) muscles form the pelvic diaphragm?

a. \_\_\_\_\_

b. \_\_\_\_\_

6. What three (3) muscles form the levator ani?

a. \_\_\_\_\_

b. \_\_\_\_\_

c. \_\_\_\_\_

7. What muscle lies in (passes through) the greater sciatic foramen?  
\_\_\_\_\_
8. What muscle forms the lateral border of the urogenital hiatus?  
\_\_\_\_\_
9. Name the peritoneal fold that, in the female, extends from the uterus to the lateral wall of the pelvis.  
\_\_\_\_\_
10. What muscle lies between the superior and inferior pelvic fascia?  
\_\_\_\_\_
11. What is the origin of the obturator artery?  
\_\_\_\_\_
12. What is the origin of the internal pudendal artery?  
\_\_\_\_\_
13. Into what vein does the internal iliac vein drain?  
\_\_\_\_\_
14. What nerve is the main nerve of the perineum and the main sensory nerve of the external genitalia?  
\_\_\_\_\_
15. What spinal segments give rise to parasympathetic fibers that innervate the structures of the pelvis?  
\_\_\_\_\_



16. What spinal segments contribute to the formation of the pudendal nerve?  
\_\_\_\_\_
17. What nervous system structure interconnects the superior hypogastric plexus with the inferior hypogastric plexus?  
\_\_\_\_\_
18. Do the ureters course (anterior or posterior) to the common iliac artery as they enter the pelvis?  
\_\_\_\_\_
19. What is the name of the muscle that forms the wall of the urinary bladder?  
\_\_\_\_\_
20. What type of muscle forms the internal urethral sphincter?  
\_\_\_\_\_
21. What type of muscle forms the external urethral sphincter?  
\_\_\_\_\_
22. Name the nerves formed by parasympathetic fibers that provide motor innervation to the urinary bladder.  
\_\_\_\_\_
23. What structures mark the superior and inferior angles of the trigone of the urinary bladder?
- a. superior angles \_\_\_\_\_
- b. inferior angle \_\_\_\_\_

24. Indicate the origin of the three (3) arteries that supply the rectum
- a. superior rectal art. \_\_\_\_\_
  - b. middle rectal art. \_\_\_\_\_
  - c. inferior rectal art. \_\_\_\_\_

25. What two (2) structures drain into the ejaculatory duct?
- a. \_\_\_\_\_
  - b. \_\_\_\_\_

26. What glands are embedded in the external urethral sphincter?
- \_\_\_\_\_

27. Name the four (4) parts of the uterine tube in order from distal to proximal
- a. \_\_\_\_\_
  - b. \_\_\_\_\_
  - c. \_\_\_\_\_
  - d. \_\_\_\_\_

28. What is the name of the large mesentery that extends from the sides of the uterus to the lateral wall and floor of the pelvis?
- \_\_\_\_\_

29. What are the two (2) main parts of the uterus?
- a. \_\_\_\_\_
  - b. \_\_\_\_\_

30. Into what veins do the right and left ovarian veins commonly drain?
- a. right ovarian vein \_\_\_\_\_
  - b. left ovarian vein \_\_\_\_\_
31. Into what veins do the right and left testicular veins drain?
- a. right testicular vein \_\_\_\_\_
  - b. left testicular vein \_\_\_\_\_
32. Name the three (3) layers of the uterine wall from deep to superficial.
- a. \_\_\_\_\_
  - b. \_\_\_\_\_
  - c. \_\_\_\_\_
33. Name the space formed where the peritoneum “folds” from the urinary bladder to the uterus.
- \_\_\_\_\_
34. Name the space formed where the peritoneum “folds” from the rectum to the uterus.
- \_\_\_\_\_
35. The perineum is divided into two (2) triangles by a line passing between the right and left ischial tuberosities. What are the names of the two triangles formed by this line?
- a. anterior triangle \_\_\_\_\_
  - b. posterior triangle \_\_\_\_\_

36. What are the boundaries of the deep perineal pouch (space)?
- a. superior boundary \_\_\_\_\_
  - b. inferior boundary \_\_\_\_\_
37. In the male, what muscle is located in the deep perineal pouch (space)?
- \_\_\_\_\_
38. In the male, what three (3) muscles are located in the superficial perineal pouch (space)?
- a. \_\_\_\_\_
  - b. \_\_\_\_\_
  - c. \_\_\_\_\_
39. The pudendal canal (Alcock's canal) is a small neurovascular passageway through which pass the pudendal vessels and nerve. This canal lies on the medial surface of what muscle of the pelvis?
- \_\_\_\_\_
40. What type of muscle forms the internal anal sphincter?
- \_\_\_\_\_
41. What type of muscle forms the external anal sphincter?
- \_\_\_\_\_
42. What anatomical landmark marks the point of anastomosis between blood supply to the anus delivered by the superior rectal artery and the inferior rectal artery?
- \_\_\_\_\_

43. What anatomical landmark marks point of transition between the part of the anus with epithelium derived from endoderm (hindgut) and the part with epithelium derived from ectoderm (proctodeum)?

---

44. What is the name of the single (unpaired) cylindrical structure forming part of the shaft of the penis?

---

45. What is the name of the paired cylindrical structures forming part of the shaft of the penis?

---

46. The skin of the scrotum is innervated by two nerves: the anterior and posterior scrotal nerves. What two (2) nerves contribute to each of these scrotal nerves?

anterior scrotal nerve

a. \_\_\_\_\_

b. \_\_\_\_\_

posterior scrotal nerve

c. \_\_\_\_\_

d. \_\_\_\_\_

47. What artery is the origin of branches that supply corpora of the penis?

---

48. What glands are located on either side of the vestibule of the vagina?

---

49. Name the peritoneal fold that, in the female, extends from the ovary to the fallopian tube.

\_\_\_\_\_

50. Not including the femoral artery, what are the two (2) main branches of the external iliac artery?

a. \_\_\_\_\_

b. \_\_\_\_\_

51. What are the eleven (11) branches of the internal iliac artery?

a. \_\_\_\_\_

b. \_\_\_\_\_

c. \_\_\_\_\_

d. \_\_\_\_\_

e. \_\_\_\_\_

f. \_\_\_\_\_

g. \_\_\_\_\_

h. \_\_\_\_\_

i. \_\_\_\_\_

j. (female) \_\_\_\_\_

k. (female) \_\_\_\_\_

52. Into what vein do each of the three (3) rectal veins drain?

a. \_\_\_\_\_

b. \_\_\_\_\_

c. \_\_\_\_\_

53. What are the three (4) parts of the male urethra?
- a. \_\_\_\_\_
  - b. \_\_\_\_\_
  - c. \_\_\_\_\_
  - d. \_\_\_\_\_
54. What is the thick external covering of the testes?
- \_\_\_\_\_
55. What is the dense plexus of veins on the surface of the testes that drains into the testicular vein?
- \_\_\_\_\_
56. What structure connects the epididymis to the ejaculatory duct?
- \_\_\_\_\_
57. What two (2) muscles lie in the deep perineal space in the male?
- a. \_\_\_\_\_
  - b. \_\_\_\_\_
58. What nerve innervates the muscles in the deep perineal space?
- \_\_\_\_\_
59. What structure in the female is the homologue of the male bulbourethral glands?
- \_\_\_\_\_
60. What nerve provides motor innervation to the external anal sphincter?
- \_\_\_\_\_

# 9 Head and Face

1. What bones are joined to form the lambda?

a. \_\_\_\_\_

b. \_\_\_\_\_

2. What bones are joined to form the bregma?

a. \_\_\_\_\_

b. \_\_\_\_\_

3. What two (2) bones contribute to the zygomatic arch?

a. \_\_\_\_\_

b. \_\_\_\_\_

4. What four (4) bones contribute to the formation of the pterion?

a. \_\_\_\_\_

b. \_\_\_\_\_

c. \_\_\_\_\_

d. \_\_\_\_\_

5. At approximately what age does the anterior fontanelle become no longer palpable?

\_\_\_\_\_

6. What structure divides the intracranial compartment into right and left halves?

\_\_\_\_\_



7. What structure divides the intracranial compartment into supratentorial and infratentorial compartments?

---

8. What are the five (5) layers of the scalp?

a. \_\_\_\_\_

b. \_\_\_\_\_

c. \_\_\_\_\_

d. \_\_\_\_\_

e. \_\_\_\_\_

9. What branch of the external carotid artery:

a. is palpable along the inferior border of the mandible?

---

b. supplies the structure of the tongue?

---

c. is palpable in the temporal fossa?

---

d. supplies part of the thyroid gland?

---

e. enters the pterygopalatine fossa?

---

10. What artery anastomoses from the front with the intraorbital branches of the ophthalmic artery?

---

11. What dural venous sinus:
- a. lies in the superior margin of the falx cerebri?  
\_\_\_\_\_
  - b. lies in the inferior margin of the falx cerebri?  
\_\_\_\_\_
  - c. lies along the petrous ridge?  
\_\_\_\_\_
  - d. lies immediately lateral to the sella turcica?  
\_\_\_\_\_
  - e. at the junction of the falx cerebri and the tentorium cerebelli?  
\_\_\_\_\_
12. Which two (2) dural venous sinuses drain directly into the jugular vein?
- a. \_\_\_\_\_
  - b. \_\_\_\_\_
13. What artery enters the cranial cavity by passing through the foramen magnum?  
\_\_\_\_\_
14. What artery enters the cranial cavity by passing through the foramen spinosum?  
\_\_\_\_\_
15. What two (2) arteries are connected by way of the anterior communication artery?
- a. \_\_\_\_\_
  - b. \_\_\_\_\_

16. What two (2) arteries are connected by way of the posterior communication artery?

a. \_\_\_\_\_

b. \_\_\_\_\_

17. What are the five (5) major intracranial branches of the internal carotid artery?

a. \_\_\_\_\_

b. \_\_\_\_\_

c. \_\_\_\_\_

d. \_\_\_\_\_

e. \_\_\_\_\_

18. What cranial nerve passes through the parotid gland?

\_\_\_\_\_

19. What are the four (4) muscles of mastication?

a. \_\_\_\_\_

b. \_\_\_\_\_

c. \_\_\_\_\_

d. \_\_\_\_\_

20. What cranial nerve mediates sensation from the:
- a. forehead over the eyebrows  
\_\_\_\_\_
  - b. skin over the maxilla  
\_\_\_\_\_
  - c. skin over the mental tubercle  
\_\_\_\_\_
21. What cranial nerve provides parasympathetic innervation to the parotid gland?
- \_\_\_\_\_
- a. What is the location of the postganglionic cell body?  
\_\_\_\_\_
22. What cranial nerve provides parasympathetic innervation to the submandibular and submaxillary glands?
- \_\_\_\_\_
- a. What is the location of the postganglionic cell body?  
\_\_\_\_\_
23. What cranial nerve provides parasympathetic innervation to the lacrimal gland?
- \_\_\_\_\_
- a. What is the location of the postganglionic cell body?  
\_\_\_\_\_

24. What cranial nerve provides motor innervation to the muscles of facial expression?

---

25. What cranial nerve provides motor innervation to the muscles of mastication?

---

26. What cranial nerve provides sensory innervation to the face?

---

a. What branch of this nerve innervates the skin over the eyebrow?

---

1) Which opening in the middle cranial fossa contains the axons of this nerve branch?

---

b. What branch of this nerve innervates the skin over the maxilla?

---

1) Which opening in the middle cranial fossa contains the axons of this nerve branch?

---

c. What branch of this nerve innervates the skin over the mental protuberance?

---

1) Which opening in the middle cranial fossa contains the axons of this nerve branch?

---

27. What foramen transmits the axons of the glossopharyngeal nerve?

---

28. What striated (skeletal) muscle is innervated by the glossopharyngeal nerve?

---

29. What special sensory functions are mediated by the glossopharyngeal nerve?

a. 

---

b. 

---

30. What foramen transmits the axons of the vagus nerve?

---

31. What striated muscles are innervated by the vagus nerve?

a. 

---

b. 

---

32. What is the effect of the vagus nerve on heart rate?

---

33. What is the effect of the vagus nerve on gastric and intestinal motility?

---

34. What special sensory functions are mediated by the vagus nerve?
- a. \_\_\_\_\_
- b. \_\_\_\_\_
35. What two foramina transmit the axons of the spinal accessory nerve?
- a. \_\_\_\_\_
- b. \_\_\_\_\_
36. What muscles are innervated by the spinal accessory nerve?
- a. \_\_\_\_\_
- b. \_\_\_\_\_
37. What foramen transmits the axons of the hypoglossal nerve?
- \_\_\_\_\_
38. What muscle innervated by the hypoglossal nerve is primarily involved in protrusion of the tongue?
- \_\_\_\_\_
39. What cranial nerve exits the skull via the stylomastoid foramen?
- \_\_\_\_\_
40. Through what foramen does the facial nerve enter the skull (exit the posterior cranial fossa)?
- \_\_\_\_\_
41. Through what foramen does the facial nerve exit the skull?
- \_\_\_\_\_

42. What are the five terminal branches of the facial nerve that emerge from the substance of the parotid gland?

a. \_\_\_\_\_

b. \_\_\_\_\_

c. \_\_\_\_\_

d. \_\_\_\_\_

e. \_\_\_\_\_

43. What two (2) nerves form the nerve of the pterygoid canal (Vidian nerve)?

a. \_\_\_\_\_

b. \_\_\_\_\_

44. What cranial nerve gives rise to the chorda tympani?

\_\_\_\_\_

45. What cranial nerve gives rise to the greater superficial petrosal nerve?

\_\_\_\_\_

46. What cranial nerve gives rise to the tympanic nerve?

\_\_\_\_\_

47. What two (2) nerves provide sensory innervation to the meninges surrounding the brain?

a. \_\_\_\_\_

b. \_\_\_\_\_



48. Other than the muscles of mastication and the muscles of the scalp, what four (4) skeletal muscles are innervated by the trigeminal nerve?

a. \_\_\_\_\_

b. \_\_\_\_\_

c. \_\_\_\_\_

d. \_\_\_\_\_

49. Other than the muscles of facial expression and the auricular muscles, what three (3) skeletal muscles are innervated by the facial nerve?

a. \_\_\_\_\_

b. \_\_\_\_\_

c. \_\_\_\_\_

50. Which intracranial foramina transmits the axons of the ophthalmic nerve?

\_\_\_\_\_

51. Which intracranial foramina transmits the axons of the maxillary nerve?

\_\_\_\_\_

52. Which intracranial foramina transmits the axons of the mandibular nerve?

\_\_\_\_\_

53. Which intracranial foramina transmits the axons of the optic nerve?

\_\_\_\_\_

54. What three (3) cranial nerves pass through the internal auditory (acoustic) meatus?

a. \_\_\_\_\_

b. \_\_\_\_\_

c. \_\_\_\_\_

55. What nerve passes through the mandibular foramen?

\_\_\_\_\_

56. What autonomic ganglion is located in the orbit?

\_\_\_\_\_

57. What autonomic ganglion is located in the pterygopalatine fossa?

\_\_\_\_\_

58. What autonomic ganglion is located immediately below the foramen ovale?

\_\_\_\_\_

59. What autonomic ganglion is located in the floor of the mouth?

\_\_\_\_\_

60. What nerve passes from the infratemporal fossa to the orbit by way of the inferior orbital fissure?

\_\_\_\_\_

61. What artery lies in the cavernous sinus?

\_\_\_\_\_

62. What nerve passes through the cavernous sinus?

---

63. What nerve passes through the sphenopalatine foramen?

---

64. What artery passes into the pterygopalatine fossa through the pterygomaxillary fissure?

---

65. What nerve exits the skull by way of the stylomastoid foramen?

---

66. Which cranial nerve gives rise to parasympathetic fibers that are part of the lesser petrosal nerve?

---

67. Which cranial nerve gives rise to parasympathetic fibers that are part of the Tympanic nerve?

---

68. Where are the postganglionic parasympathetic nerve cell bodies that receive synaptic input from the fibers of the lesser petrosal nerve?

---

69. What nerve emerges from the mental foramen?

---

70. The glabella is a feature of what bone?

---

71. The cribriform plate is a feature of what bone?

---

72. The sella turcica is a feature of what bone?

---

73. The styloid process is a feature of what bone?

---

74. What two (2) bones form the clivus?

a. 

---

b. 

---

75. What veins transmit blood from the scalp to the dural venous sinuses?

---

76. What veins are located between the inner and outer layers of the calvarium?

---

77. What two (2) venous structures merge to form the straight sinus?

---

78. What nerve exits the skull by way of the petrotympanic fissure?

---

# 10 Mouth and Pharynx

1. What are the two (2) main muscles are used to close the mouth?

a. \_\_\_\_\_

b. \_\_\_\_\_

2. What muscle forms the floor of the oral cavity?

\_\_\_\_\_

3. What muscle forms that palatoglossal arch?

\_\_\_\_\_

a. What nerve provides motor innervation to this muscle?

\_\_\_\_\_

4. What muscle forms the palatopharyngeal arch?

\_\_\_\_\_

a. What nerve provides motor innervation to this muscle?

\_\_\_\_\_

5. What muscle forms the anterior pillar of the tonsillar fossa?

\_\_\_\_\_

6. What muscle forms the posterior pillar of the tonsillar fossa?

\_\_\_\_\_

7. What nerve provides sensory innervation to the mucosal lining of the tonsillar fossa?

---

8. What two (2) muscles act on the soft palate?

a. \_\_\_\_\_

b. \_\_\_\_\_

9. What nerve provides motor innervation to the superior, middle and inferior pharyngeal constrictor muscles?

---

10. What nerve provides motor innervation to the intrinsic muscles of the tongue?

---

11. What nerve provides motor innervation to MOST of the extrinsic muscles of the tongue?

---

12. Which of the extrinsic muscles of the tongue is NOT innervated like the others?

---

a. What nerve provides motor innervation to this muscle?

---

13. What nerve innervates mechanical and thermal receptors on the anterior 2/3 of the tongue?

---

14. What nerve innervates mechanical and thermal receptors on the posterior 1/3 of the tongue?

---

15. What nerve innervates taste buds on the anterior 2/3 of the tongue?

---

16. What nerve innervates taste buds on the posterior 1/3 of the tongue?

---

17. What cranial nerve provides motor innervation to the submandibular salivary glands?

---

18. What cranial nerve provides motor innervation to the parotid salivary glands?

---

19. What nerve provides sensory innervation to the gingiva of the maxillary teeth?

---

20. What nerve provides sensory innervation to the gingiva of the mandibular teeth?

---

21. What nerve provides sensory innervation to the mucosa overlying the hard palate?

---

22. What nerve provides sensory innervation to the mucosa overlying the soft palate?  
\_\_\_\_\_
23. What feature of the tongue marks the attachment of the thyroglossal duct?  
\_\_\_\_\_
24. What nerve provides motor innervation to each of the following muscles of the pharynx?
- a. palatopharyngeus \_\_\_\_\_
  - b. salpingopharyngeus \_\_\_\_\_
  - c. stylopharyngeus \_\_\_\_\_
25. What structure lies between the palatoglossal and palatopharyngeal folds?  
\_\_\_\_\_
26. What nerve innervates the buccinator muscle?  
\_\_\_\_\_
27. What are the origins of each of the three (3) pharyngeal constrictors?
- a. superior constrictor \_\_\_\_\_
  - b. middle constrictor \_\_\_\_\_
  - c. inferior constrictor \_\_\_\_\_
28. Name the three (3) pharyngeal muscles other than the constrictor muscles.
- a. \_\_\_\_\_
  - b. \_\_\_\_\_
  - c. \_\_\_\_\_



29. What tubular structure connects the nasopharynx with the tympanic cavity?

---

30. Name the potential space located between the buccopharyngeal fascia and the prevertebral fascia.

---

# 11 Neck and Larynx

1. What are the four (4) parts of the deep cervical fascia?

a. \_\_\_\_\_

b. \_\_\_\_\_

c. \_\_\_\_\_

d. \_\_\_\_\_

2. What two (2) muscles are ensheathed by the investing layers of the deep cervical fascia?

a. \_\_\_\_\_

b. \_\_\_\_\_

3. What four (4) structures are enclosed within the pretracheal layer of deep cervical fascia?

a. \_\_\_\_\_

b. \_\_\_\_\_

c. \_\_\_\_\_

d. \_\_\_\_\_

4. What are the three (3) main structures enclosed within the carotid sheath?

a. \_\_\_\_\_

b. \_\_\_\_\_

c. \_\_\_\_\_

5. What are the boundaries of the anterior triangle of the neck?

a. \_\_\_\_\_

b. \_\_\_\_\_

c. \_\_\_\_\_

6. What are the boundaries of the carotid triangle?

a. \_\_\_\_\_

b. \_\_\_\_\_

c. \_\_\_\_\_

7. What are the boundaries of the submandibular triangle?

a. \_\_\_\_\_

b. \_\_\_\_\_

c. \_\_\_\_\_

8. What are the boundaries of the submental triangle?

a. \_\_\_\_\_

b. \_\_\_\_\_

c. \_\_\_\_\_

9. What muscles are boundaries of the muscular triangle?

a. \_\_\_\_\_

b. \_\_\_\_\_

c. \_\_\_\_\_

10. What are the boundaries of the posterior triangle of the neck?

a. \_\_\_\_\_

b. \_\_\_\_\_

c. \_\_\_\_\_

11. What muscles comprise the infrahyoid muscles of the neck?

a. \_\_\_\_\_

b. \_\_\_\_\_

c. \_\_\_\_\_

d. \_\_\_\_\_

12. What muscles comprise the suprahyoid muscles of the neck?

a. \_\_\_\_\_

b. \_\_\_\_\_

c. \_\_\_\_\_

d. \_\_\_\_\_

13. What muscle abducts the vocal folds?

\_\_\_\_\_

14. What nerve provides motor innervation to this muscle?

\_\_\_\_\_

15. What two muscles adduct the vocal folds?

a. \_\_\_\_\_

b. \_\_\_\_\_

16. What nerve provides motor innervation to these muscles?

---

17. What laryngeal muscle lies on the external surface of the larynx?

---

18. What nerve provides motor innervation to this muscle?

---

19. What nerve provides sensory innervation to the mucosal lining the internal surface of the larynx?

---

20. The roots of the brachial plexus course through the root of the neck by passing between which two of the scalene muscles?

a. \_\_\_\_\_

b. \_\_\_\_\_

21. The subclavian artery courses through the root of the neck by passing

\_\_\_\_\_ to the anterior scalene muscle.

22. The subclavian vein courses through the root of the neck by passing

\_\_\_\_\_ to the anterior scalene muscle.

23. What is the anatomical landmark that marks the point where the subclavian artery becomes the axillary artery?

---

24. What are the five (5) branches of the subclavian artery?

a. \_\_\_\_\_

b. \_\_\_\_\_

c. \_\_\_\_\_

d. \_\_\_\_\_

e. \_\_\_\_\_

25. What artery is the origin of the superior thyroid artery?

\_\_\_\_\_

26. What artery is the origin of the inferior thyroid artery?

\_\_\_\_\_

27. What veins merge to form the retromandibular vein?

a. \_\_\_\_\_

b. \_\_\_\_\_

28. What veins merge to form the external jugular vein?

a. \_\_\_\_\_

b. \_\_\_\_\_

29. What veins merge to form the brachiocephalic vein?

a. \_\_\_\_\_

b. \_\_\_\_\_

30. What spinal segments give rise to the phrenic nerve?

\_\_\_\_\_

31. What spinal segments give rise to the ansa cervicalis?

---

32. At what vertebral level does the common carotid artery bifurcate to form the internal and external carotid arteries?

---

33. Sympathetic chain ganglia from what segmental levels fuse to form the superior cervical ganglion?

---

34. Sympathetic chain ganglia from what segmental levels fuse to form the middle cervical ganglion?

---

35. Sympathetic chain ganglia from what segmental levels fuse to form the inferior cervical ganglion?

---

36. Name the six (6) branches of the external carotid artery (not including the two terminal branches).

a. \_\_\_\_\_

b. \_\_\_\_\_

c. \_\_\_\_\_

d. \_\_\_\_\_

e. \_\_\_\_\_

f. \_\_\_\_\_

37. Name the two (2) terminal branches of the external carotid artery.
- a. \_\_\_\_\_
  - b. \_\_\_\_\_
38. What are the three (3) branches of the thyrocervical trunk?
- a. \_\_\_\_\_
  - b. \_\_\_\_\_
  - c. \_\_\_\_\_
39. What are the four (4) branches of the cervical plexus?
- a. \_\_\_\_\_
  - b. \_\_\_\_\_
  - c. \_\_\_\_\_
  - d. \_\_\_\_\_
40. What muscle divides the subclavian artery into three parts?
- \_\_\_\_\_
41. Into what veins do the three (3) thyroid veins drain?
- a. \_\_\_\_\_
  - b. \_\_\_\_\_
  - c. \_\_\_\_\_
42. What two (2) triangles are found within the posterior triangle of the neck?
- a. \_\_\_\_\_
  - b. \_\_\_\_\_



43. What are the borders of the occipital triangle?

a. \_\_\_\_\_

b. \_\_\_\_\_

c. \_\_\_\_\_

44. What are the borders of the omoclavicular triangle?

a. \_\_\_\_\_

b. \_\_\_\_\_

c. \_\_\_\_\_

45. What muscle divides the neck into anterior and posterior triangles?

\_\_\_\_\_

46. What muscle separates the subclavian artery from the subclavian vein in the root of the neck?

\_\_\_\_\_

47. What nerve provides motor innervation to the sternocleidomastoid?

\_\_\_\_\_

48. What is the name of the posterior primary ramus of the C2 spinal nerve?

\_\_\_\_\_

49. What type of receptors are found in each of the following?

a. carotid body \_\_\_\_\_

b. carotid sinus \_\_\_\_\_

50. Name the three (3) major branches of the arch of the aorta in order from proximal to distal.

a. \_\_\_\_\_

b. \_\_\_\_\_

c. \_\_\_\_\_

51. What nerve in the neck lies on the anterior surface of the anterior scalene?

\_\_\_\_\_

52. Beneath what structure does the recurrent laryngeal nerve “recur” on each side?

a. right side \_\_\_\_\_

b. left side \_\_\_\_\_

53. What is the origin of each of the following arteries that supply the thyroid gland?

a. inferior thyroid artery \_\_\_\_\_

b. superior thyroid artery \_\_\_\_\_

54. Into what veins do each of the three (3) thyroid veins drain?

a. superior thyroid vein \_\_\_\_\_

b. middle thyroid vein \_\_\_\_\_

c. inferior thyroid vein \_\_\_\_\_

55. What vertebral body would be crossed by a horizontal line passing posteriorly from superior edge of the thyroid cartilage?

\_\_\_\_\_

56. Name the membrane that fills the space anteriorly between the thyroid cartilage and the cricoid cartilage.

---

57. Name the membrane that fills the space anteriorly between the hyoid bone and the thyroid cartilage.

---

58. What laryngeal muscle is NOT innervated by the inferior laryngeal nerve?

---

59. What two (2) structures pass through the thyrohyoid membrane?

a. nerve \_\_\_\_\_

b. artery \_\_\_\_\_

60. What nerve provides sensory innervation to the mucosal lining of the larynx?

---

61. Name the membrane through which the internal laryngeal nerve passes to enter the larynx.

---

62. Name the laryngeal cartilage that serves as the posterior attachment of the vocal ligament.

---

63. What ligamentous structure does the vertebral artery pass through immediately before entering the skull?

---

64. What nerve innervates the platysma muscle?

---

65. Which tracheal rings are covered by the isthmus of the thyroid gland?

---

66. What are the seven (7) tributaries of the internal jugular vein?

a. 

---

b. 

---

c. 

---

d. 

---

e. 

---

f. 

---

g. 

---

67. What two (2) branches of the vagus nerve arise in the jugular fossa?

a. 

---

b. 

---

68. Which pharyngeal constrictor lies in proximity to the superior parathyroid gland?

---

69. What nerve passes through the thyrohyoid membrane?

---

70. Which branch of the external carotid artery carries postganglionic sympathetic fibers to the sublingual salivary glands?

---

71. Which triangle of the neck do the subclavian artery and vein pass through?  
\_\_\_\_\_
72. Through which triangle of the neck does the spinal accessory nerve pass?  
\_\_\_\_\_
73. Which part of the brachial plexus passes between the anterior and middle scalene muscles?  
\_\_\_\_\_
74. Which cervical sympathetic ganglia contributes fibers to the brachial plexus?  
\_\_\_\_\_
75. What six (6) cartilages comprise the larynx?
- a. \_\_\_\_\_
  - b. \_\_\_\_\_
  - c. \_\_\_\_\_
  - d. \_\_\_\_\_
  - e. \_\_\_\_\_
  - f. \_\_\_\_\_
76. Name the two (2) mucosal folds that border the laryngeal ventricle.
- a. \_\_\_\_\_
  - b. \_\_\_\_\_
77. What muscle form part of the laryngeal vocal fold?  
\_\_\_\_\_

78. Which cervical vertebra typically does not have a transverse foramen?  
\_\_\_\_\_
79. What nerve lies adjacent to the external jugular vein on the superficial surface of the sternocleidomastoid muscle?  
\_\_\_\_\_
80. What five (5) nerves emerge from the posterior edge of the sternocleidomastoid into the posterior triangle of the neck?
- a. \_\_\_\_\_
  - b. \_\_\_\_\_
  - c. \_\_\_\_\_
  - d. \_\_\_\_\_
  - e. \_\_\_\_\_
81. What nerve passes between the middle and posterior scalene muscles into the posterior triangle of the neck?  
\_\_\_\_\_
82. What two (2) arteries course laterally on the anterior scalene muscle into the posterior triangle of the neck?
- a. \_\_\_\_\_
  - b. \_\_\_\_\_
83. Does the omohyoid muscle lie (anterior/posterior) to the external jugular vein in the carotid triangle?  
\_\_\_\_\_

84. Which of the infrahyoid (strap) muscles does not have an attachment to the hyoid bone?

---

# 12 Orbit

1. What are the three (3) openings located in the posterior part of the orbit?
  - a. \_\_\_\_\_
  - b. \_\_\_\_\_
  - c. \_\_\_\_\_
  
2. What are the two (2) main structures that pass through the optic canal?
  - a. \_\_\_\_\_
  - b. \_\_\_\_\_
  
3. What are the main structures that pass through the superior and inferior orbital fissures?
  - a. \_\_\_\_\_ nerve
  - b. \_\_\_\_\_ nerve
  - c. \_\_\_\_\_ nerve
  - d. \_\_\_\_\_ nerve
  - e. \_\_\_\_\_ nerve
  - f. \_\_\_\_\_ nerve
  - g. \_\_\_\_\_ vein
  - h. \_\_\_\_\_ vein



4. What are the main structures that pass through the common tendinous ring?
- a. \_\_\_\_\_ nerve
  - b. \_\_\_\_\_ nerve
  - c. \_\_\_\_\_ nerve
  - d. \_\_\_\_\_ nerve
5. What is the name of the thin membrane that lines the surface of the cornea and deep surface of the upper and lower eye lids (palpebrae)?
- \_\_\_\_\_
6. What two (2) muscles play a role in elevation of the upper eyelid?
- a. \_\_\_\_\_
  - b. \_\_\_\_\_
7. What are the two (2) main types of glands in the upper eyelid?
- a. \_\_\_\_\_
  - b. \_\_\_\_\_
8. Describe the location of the lacrimal gland in the orbit.
- \_\_\_\_\_
9. Where does the nasolacrimal duct drain?
- \_\_\_\_\_
10. What cranial nerve provides motor innervation to the lacrimal gland?
- \_\_\_\_\_

11. Which extraocular muscle does NOT originate from the common tendinous ring?

---

12. What nerve provides motor innervation to the levator palpebrae superioris muscle?

---

13. Where are the nerve cell bodies that provide motor innervation to Mueller's muscle?

---

14. What are the three (3) branches of the ophthalmic artery in the orbit?

a. \_\_\_\_\_

b. \_\_\_\_\_

c. \_\_\_\_\_

15. What nerve enters the orbit by way of the inferior orbital fissure?

---

16. What nerve gives rise to the short ciliary nerves?

---

17. What nerve gives rise to the long ciliary nerves?

---

18. What artery gives rise to the central artery of the retina?

---

19. Into what venous structure do the superior and inferior ophthalmic veins drain?

---

# 13 Eye

1. What are the three (3) layers of the eye? (List layers from superficial to deep.)

a. \_\_\_\_\_

b. \_\_\_\_\_

c. \_\_\_\_\_

2. What nerve provides sensory innervation to the cornea?

\_\_\_\_\_

3. What structure separates the anterior chamber from the posterior chamber of the eye?

\_\_\_\_\_

4. What fluid is found in the anterior chamber of the eye?

\_\_\_\_\_

5. What fluid is found in the posterior chamber of the eye?

\_\_\_\_\_

6. What two (2) muscles are located in the iris AND what division of the autonomic nervous system provides motor innervation to each?

Muscle

Autonomic Division

a. \_\_\_\_\_

b. \_\_\_\_\_

7. What structure connects the lens to the ciliary muscle?  
\_\_\_\_\_
8. What is the effect of contraction of the ciliary muscle?  
\_\_\_\_\_
9. Where are the nerve cell bodies that provide motor innervation to the ciliary muscle?
- a. preganglionic cell \_\_\_\_\_
  - b. postganglionic cell \_\_\_\_\_
10. Where are the cell bodies that provide motor innervation to the pupillary constrictors?
- a. preganglionic cell \_\_\_\_\_
  - b. postganglionic cell \_\_\_\_\_
11. Where are the cell bodies that provide motor innervation to the pupillary dilators?
- a. preganglionic cell \_\_\_\_\_
  - b. postganglionic cell \_\_\_\_\_
12. What structure produces aqueous humor?  
\_\_\_\_\_
13. Through what opening does aqueous humor normally pass to exit the eye?  
\_\_\_\_\_
14. Where is this opening located?  
\_\_\_\_\_

15. What is the optic disc?

---

16. What is the physiologic cup?

---

17. What is the macula lutea?

---

18. What is the fovea centralis?

---

19. What retinal structure is associated with the “blind spot” in the visual field?

---

20. What are the two (2) types of photoreceptor cells?

a. \_\_\_\_\_

b. \_\_\_\_\_

21. Which photoreceptor cell is heavily concentrated in the fovea centralis?

---

22. What vessel is the origin of the central artery of the retina?

---

23. The superior and inferior ophthalmic veins receive venous blood from intraorbital structures. Blood in these vessels can drain out of the orbit by passing posteriorly, anteriorly or inferiorly, depending on intravenous pressure. What are the three (3) vascular structures that receive venous blood from the ophthalmic veins?

- a. \_\_\_\_\_ posteriorly
- b. \_\_\_\_\_ inferiorly
- c. \_\_\_\_\_ anteriorly

# 14 Ear

1. What peripheral nerves provide sensory innervation to the auricle?

a. \_\_\_\_\_

b. \_\_\_\_\_

2. Which branchial arch is the origin of each of the following ossicles?

Auditory Ossicle

Branchial Arch

Malleus

\_\_\_\_\_

Incus

\_\_\_\_\_

Stapes

\_\_\_\_\_

3. Which of the ossicles is attached to the internal surface of the tympanic membrane?

\_\_\_\_\_

4. Which of the ossicles is attached to the oval window?

\_\_\_\_\_

5. What muscle attaches to the malleus?

\_\_\_\_\_

a. What cranial nerve innervates this muscle?

\_\_\_\_\_



6. What muscle attaches to the stapes?

---

a. What cranial nerve innervates this muscle?

---

7. What cranial nerve transmits auditory impulses to the brainstem?

---

8. What foramen of the skull transmits the axons of the vestibulocochlear nerve?

---

9. What vestibular system receptor structure is responsive to rotatory (angular) acceleration and deceleration of the head?

---

10. What vestibular system receptor structure is responsive to linear acceleration and deceleration of the head?

---

11. What fluid substance is found in the scala tympani?

---

12. What fluid substance is found in the scala vestibuli?

---

13. What fluid substance is found in the scala media?

---

14. What fluid substance is found in the semicircular canals?  
\_\_\_\_\_
15. Which vestibular receptor structures are associated with otoconia?  
\_\_\_\_\_
16. Where are the cell bodies of the afferent nerve fibers of the cochlear nerve?  
\_\_\_\_\_
17. Where are the cell bodies of the afferent nerve fibers of the vestibular nerve?  
\_\_\_\_\_
18. In which quadrant of the tympanic membrane can you see the “cone of light”?  
\_\_\_\_\_
19. Which two nerves pass through the tympanic cavity?  
a. \_\_\_\_\_  
b. \_\_\_\_\_
20. Which pharyngeal arch gives rise to the stapes?  
\_\_\_\_\_
21. Which pharyngeal arch gives rise to the malleus?  
\_\_\_\_\_



## Part 2: Answer Key

# 1 Back and Spine

1.
  - a. eight (8)
  - b. twelve (12)
  - c. five (5)
  - d. five (5)
2.
  - a. cervical spine
  - b. lumbar spine
3.
  - a. anterior longitudinal ligament
  - b. ligamentum flavum
  - c. interspinous ligament
  - d. posterior longitudinal ligament
4. ligamentum nuchae
5. zygapophyseal (facet) joint
6. cervical vertebrae
7. C7
8. C2 (axis)
9. C7
10.
  - a. lamina
  - b. pedicle
11.
  - a. nucleus pulposus
  - b. anulus fibrosus
12. posterior atlanto-occipital membrane
13. internal vertebral plexus (Batson's plexus)
14. thoracolumbar fascia (thoracodorsal fascia, lumbodorsal fascia)

15.
  - a. trapezius
  - b. latissimus dorsi
  - c. rhomboid major
16.
  - a. splenius capitis
  - b. splenius cervicis
17. erector spinae muscles
18. transversospinal muscles
19.
  - a. rectus capitus posterior major
  - b. obliquus capitus superior
  - c. obliquus capitus inferior
20.
  - a. vertebral artery
  - b. suboccipital nerve
21. C2
22. vertebral artery
23. L1 or L2
24. cauda equina
25. filum terminale (internum)
26. lumbar cistern
27. coccygeal ligament
28. denticulate ligament
29.
  - a. superior margin of the iliac crest
  - b. posterior margin of the external oblique
  - c. anterior margin of the latissimus dorsi
30. nucleus pulposis
31.
  - a. iliocostalis
  - b. longissimus
  - c. spinalis

- 32.
  - a. semispinalis
  - b. multifidus
  - c. rotatores
  
- 33.
  - a. cruciform ligament
  - b. apical ligament
  - c. alar ligament
  - d. tectorial membrane
  
- 34. suboccipital nerve
  
- 35. conus medullaris
  
- 36. S2

## 2 Upper Limb

1.
  - a. costocoracoid membrane
  - b. suspensory ligament of the axilla
2. cephalic vein
3. cephalic vein
4.
  - a. C8
  - b. C6
  - c. C7
5. median antebrachial veins
6. median cubital (antecubital) vein
7. musculocutaneous nerve
8. inferior border of the teres major
9. medial and lateral borders of the pectoralis minor
10.
  - a. superior thoracic artery
  - b. thoracoacromial artery and lateral thoracic artery
  - c. subscapular artery  
anterior humeral circumflex artery  
posterior humeral circumflex artery
11. coracoid process
12. lateral lip of the intertubercular groove
13. anterior surface of the medial border of the scapula
14. lateral 1/3 of the clavicle, spine of the scapula, acromion process
15. floor of the intertubercular groove



16. lesser tuberosity of the humerus
17. deltoid tubercle of the humerus
18. subscapularis
19. serratus anterior
20. floor of the intertubercular groove
21. lateral border of the first rib
22.
  - a. long head of the triceps
  - b. lateral head of the triceps
  - c. inferior margin of the teres minor
  - d. superior margin of the teres major
23.
  - a. axillary nerve
  - b. posterior humeral circumflex artery
24. musculocutaneous nerve
25. radial nerve
26. radial nerve
27.
  - a. radial artery
  - b. ulnar artery
28. radial tuberosity
29. coronoid process of the ulna
30. median cubital (antecubital) vein
31.
  - a. pronator teres
  - b. brachioradialis
32.
  - a. brachialis
  - b. supinator
33. ulnar nerve

- 34.
  - a. pronator teres
  - b. flexor carpi radialis
  - c. palmaris longus
  - d. flexor carpi ulnaris
  
- 35. flexor digitorum superficialis
  
- 36.
  - a. flexor digitorum profundus
  - b. flexor pollicis longus
  - c. pronator quadratus
  
- 37. flexor carpi ulnaris
  
- 38. palmaris longus
  
- 39. flexor digitorum profundus
  
- 40.
  - a. supinator
  - b. brachioradialis
  
- 41. radial nerve
  
- 42.
  - a. abductor digiti minimi
  - b. flexor digiti minimi
  - c. opponens digiti minimi
  
- 43.
  - a. abductor pollicis brevis
  - b. flexor pollicis brevis
  - c. opponens pollicis brevis
  - d. adductor pollicis
  
- 44. flexor pollicis brevis
  
- 45. palmar interossei
  
- 46. dorsal interossei
  
- 47. ulnar nerve
  
- 48. superficial branch of the ulnar nerve

- 49. glenoid labrum
- 50.
  - a. trapezoid ligament
  - b. conoid ligament
- 51. coraco-acromial ligament
- 52.
  - a. scaphoid
  - b. lunate
  - c. triquetrum
  - d. pisiform
- 53.
  - a. trapezium
  - b. trapezoid
  - c. capitate
  - d. hamate
- 54.
  - a. profunda brachii artery
  - b. radial nerve
- 55. circumflex scapular artery
- 56. extensor pollicis longus
- 57. radial artery
- 58. scaphoid (navicular)
- 59. metacarpo-phalangeal joint (MC-P joint)
- 60.
  - a. flexion
  - b. extension
  - c. extension
- 61.
  - a. lateral head
  - b. medial head
- 62. ulnar artery
- 63. posterior interosseous artery

- 64.
  - a. superior ulnar collateral artery
  - b. posterior ulnar recurrent artery
  
- 65.
  - a. inferior ulnar collateral artery
  - b. anterior ulnar recurrent artery
  
- 66.
  - a. middle collateral artery
  - b. interosseous recurrent artery
  
- 67.
  - a. radial collateral artery
  - b. radial recurrent artery
  
- 68. infero-medially from radius to ulna or supero-laterally from ulna to radius
  
- 69. scaphoid (navicular)
  
- 70.
  - a. profunda (deep) brachial artery
  - b. superficial ulnar collateral artery
  - c. inferior ulnar collateral artery
  
- 71.
  - a. ascending branch
  - b. middle collateral artery
  - c. radial collateral artery
  
- 72. suprascapular nerve
  
- 73. subscapularis
  
- 74. radius (radial tuberosity)
  
- 75. ulna (ulnar tuberosity)
  
- 76.
  - a. scaphoid
  - b. lunate
  
- 77. C5, C6, C7
  
- 78.
  - a. upper subscapular nerve
  - b. middle subscapular nerve (thoracodorsal nerve)
  - c. lower subscapular nerve

- 79. adductor pollicis
- 80. flexor carpi ulnaris
- 81. pronator teres
- 82. supinator

# 3 Lower Limb

1.
  - a. os coxae (innominate bone)
  - b. sacrum
2.
  - a. ilium
  - b. ischium
  - c. pubis
3.
  - a. anterior superior iliac spine (ASIS)
  - b. pubic tubercle
4.
  - a. 126 degrees (range 115 – 140)
5.
  - a. 7 degrees – males and 12 degrees – females
6. fascia lata
7. iliotibial band (tract)
8. cribriform fascia
9. femoral vein
10. popliteal vein
11. L2, L3, L4
12. L2, L3, L4
13. deep fibular (peroneal) nerve
14. anterior superior iliac spine
15. anterior inferior iliac spine
16. lesser trochanter

17. adductor magnus
18. femoral artery
19.
  - a. inguinal ligament
  - b. adductor longus
  - c. sartorius
20.
  - a. femoral vein
  - b. femoral artery
  - c. femoral nerve
21. medial
22. deep inguinal lymph nodes (node of Cloquet)
23. femoral nerve
24. saphenous nerve
25. lateral femoral cutaneous nerve
26. obturator nerve
27. profunda femoris artery
28. greater trochanter of the femur
29.
  - a. sartorius
  - b. gracilis
  - c. semitendinosus
30.
  - a. tibial nerve
  - b. common fibular (peroneal) nerve
31. piriformis
32. tibial nerve
33. sural nerve
34. common fibular nerve

- 35.
  - a. tibialis anterior
  - b. extensor hallucis longus
  - c. extensor digitorum
  - d. fibularis tertius
  
- 36. anterior tibial nerve
  
- 37.
  - a. gastrocnemius
  - b. soleus
  - c. plantaris
  
- 38.
  - a. tibialis posterior
  - b. flexor hallucis longus
  - c. flexor digitorum longus
  - d. popliteus
  
- 39. dorsalis pedis artery
  
- 40.
  - a. plantar flexion
  - b. eversion
  
- 41. superficial fibular nerve
  
- 42.
  - a. gastrocnemius
  - b. popliteus
  
- 43. calcaneus
  
- 44. saphenous nerve
  
- 45. tibial nerve
  
- 46.
  - a. iliofemoral ligament
  - b. ischiofemoral ligament
  - c. pubofemoral ligament
  
- 47. obturator artery
  
- 48. profunda femoris artery
- 49. posterior cruciate ligament



50. medial ligament of the ankle
51. posterior tibial artery
52. a. profunda (deep) femoral artery  
b. superficial circumflex iliac artery  
c. superficial external pudendal artery  
d. superficial epigastric artery  
e. deep external pudendal artery  
f. descending genicular artery

# 4 Thoracic Wall

1.
  - a. manubrium
  - b. body
  - c. xiphoid process
2. 2nd rib
3. ribs 1-7
4. T5
5. T4
6.
  - a. innermost intercostal
  - b. internal intercostal
7.
  - a. internal thoracic artery
  - b. aorta
8. right
9.
  - a. vein
  - b. artery
  - c. nerve
10.
  - a. depresses lower ribs
  - b. elevates upper ribs
11.
  - a. lateral thoracic artery
  - b. internal thoracic artery
12.
  - a. musculophrenic artery
  - b. superior epigastric artery
13. T4/T5
14. 6th costal cartilage

# 5 Pleura and Lungs

1.
  - a. costal pleura
  - b. mediastinal pleura
  - c. diaphragmatic pleura
  - d. cervical pleura
2. azygos vein
3. arch of the aorta
4. pulmonary ligament
5. T4 – T5
6.
  - a. accessory hemiazygos vein
  - b. azygos v.
7. right
8.
  - a. 8th rib
  - b. 10th rib
  - c. 12th rib
9. 6th costal cartilage
10. 4th costal cartilage
11.
  - a. 6th rib
  - b. 8th rib
  - c. 10th rib
12. 6th costal cartilage
13. 4th costal cartilage
14.
  - a. T3
  - b. 5th
  - c. 6th

15.
  - a. 5th rib
  - b. 4th
16. C3, C4, C5
17. right superior lobe
18. anterior scalene
19. anterior (the phrenic nerve lies anterior to the root of the lung)
20. pericardiophrenic artery and vein

# 6 Mediastinum

1.
  - a. sternal angle (angle of Louis)
  - b. T4-T5 intervertebral disc
  
2.
  - a. anterior interventricular artery
  - b. circumflex artery
  - c. left marginal artery.
  - d. lateral (diagonal)
  
3.
  - a. posterior interventricular artery
  - b. right marginal artery
  - c. AV nodal branch
  - d. SA nodal branch
  
4. tricuspid valve
  
5.
  - a. intermediolateral nucleus.
  - b. superior, middle, inferior cervical gang.
  - c. dorsal motor nucleus
  - d. cardiac plexus
  
6.
  - a. brachiocephalic trunk
  - b. left common carotid artery
  - c. left subclavian artery
  
7. superior vena cava
  
8. right atrium
  
9. right pulmonary artery
  
10. anterior cardiac veins
  
11. esophagus
  
12.
  - a. left internal jugular vein
  - b. left subclavian vein

13. anterior
14. anterior
15. anterior
16. posterior
17. posterior
18. posterior
19. posterior
20. right
21. anterior
22. subclavian artery
23. vena caval hiatus
24. anterior
25. posterior
26.
  - a. T12
  - b. T8
  - c. T10
27. the second intercostal space on the right side along the lateral sternal border
28. the fifth intercostal space on the left side along the lateral sternal border
29. the second intercostal space on the left side along the lateral sternal border
30. the fifth intercostal space on the left side on or near the midclavicular line
31. parietal layer of serous pericardium
32. right ventricle

33. right coronary artery
34. thoracic aorta
35. left pulmonary artery

# 7 Abdomen

1. transversalis fascia
2. transversalis fascia
3.
  - a. inferior epigastric artery
  - b. deep circumflex iliac artery
4.
  - a. superficial circumflex iliac artery
  - b. superficial epigastric artery
5. superior epigastric artery
6. T10
7. inferior epigastric artery
8.
  - a. anterior superior iliac spine
  - b. pubic tubercle
9. invagination of the transversalis fascia
10. opening in the aponeurosis of the external oblique
11.
  - a. femoral vein
  - b. femoral artery
  - c. femoral nerve
12.
  - a. external oblique
  - b. internal oblique
  - c. transversalis fascia
13. internal oblique
14. genital branch of the genitofemoral nerve
15. epididymis



16. peritoneum
17. a. inferior vena cava  
b. left renal vein
18. a. gastrophrenic ligament  
b. gastrosplenic ligament  
c. gastrocolic ligament
19. a. hepatogastric ligament  
b. hepatoduodenal ligament
20. a. hepatic artery  
b. portal vein  
c. bile duct
21. a. striated  
b. both striated and smooth  
c. smooth
22. a. vagus nerve  
b. vagus nerve  
c. vagus nerve
23. a. cardia  
b. fundus  
c. body  
d. pylorus
24. celiac artery
25. a. right gastric artery (common) hepatic artery  
b. left gastric artery celiac trunk
26. a. right gastroepiploic artery gastroduodenal artery  
b. left gastroepiploic artery splenic artery
27. a. left gastric artery  
b. splenic artery  
c. (common) hepatic artery

28.
  - a. right gastric artery
  - b. gastroduodenal artery
  - c. proper hepatic artery
29.
  - a. right gastroepiploic artery
  - b. superior pancreaticoduodenal artery
30.
  - a. splenic vein
  - b. superior mesenteric vein
31.
  - a. cystic duct
  - b. common hepatic duct
32.
  - a. common bile duct
  - b. main pancreatic duct (duct of Wirsung)
33. 2nd part (descending part) through the sphincter of Oddi
34. major duodenal papilla
35. accessory pancreatic duct (duct of Santorini)
36. L3
37. superior mesenteric artery
38. ligament of Treitz
39. parts 2 (descending), 3 (horizontal) and 4 (ascending)
40. 1st and 2nd parts
41.
  - a. 3rd (horizontal) part of the duodenum
  - b. transverse colon
42. descending colon and sigmoid colon
43. descending colon and sigmoid colon
44. ascending colon and descending colon

- 45.
  - a. portal vein
  - b. hepatic artery
  - c. bile duct
- 46. falciform ligament
- 47.
  - a. quadrate lobe
  - b. caudate lobe
- 48. umbilical vein
- 49. fetal ductus venosus
- 50. posterior
- 51. anterior
- 52.
  - a. inferior phrenic artery
  - b. abdominal aorta
  - c. renal artery
- 53. T5 – T8
- 54. T9 – T11
- 55. inferior epigastric vessels
- 56. obliterated umbilical artery
- 57. L4
- 58. L5
- 59.
  - a. inferior pancreaticoduodenal artery
  - b. intestinal arteries
  - c. ileocolic artery
  - d. right colic artery
  - e. middle colic artery
- 60.
  - a. left colic artery
  - b. sigmoid arteries
  - c. superior rectal artery

- 61. right and left lumbar lymphatic trunks
- 62.
  - a. ilioinguinal nerve
  - b. genital branch of the genitofemoral nerve
- 63. above
- 64. superior hypogastric plexus
- 65. ileum
- 66.
  - a. teniae mesocolica
  - b. teniae omentalis
  - c. teniae libra
- 67. genitofemoral nerve
- 68.
  - a. superficial (fatty) layer (Camper's fascia)
  - b. deep (membranous) layer (Scarpa's fascia)
- 69. external spermatic fascia
- 70. deep fascia of the penis (Buck's fascia)
- 71.
  - a. iliohypogastric nerve
  - b. ilioinguinal nerve
  - c. genitofemoral nerve
  - d. lateral femoral cutaneous nerve
  - e. femoral nerve
  - f. obturator nerve
  - g. accessory obturator nerve
  - h. lumbosacral trunk
- 72.
  - a. lumbar veins
  - b. right gonadal (testicular and ovarian) veins
  - c. renal veins
  - d. right suprarenal vein
  - e. right inferior phrenic vein
  - f. hepatic vein
- 73.
  - a. splenic artery
  - b. celiac artery

- c. hepatic artery
  - d. splenic artery
  - e. gastroduodenal artery
74. a. psoas major  
b. quadratus lumborum
75. a. spleen  
b. stomach  
c. pancreas
76. a. latissimus dorsi  
b. external oblique  
c. iliac crest
77. a. rectus abdominus  
b. inferior epigastric vessels  
c. inguinal ligament
78. ligamentum teres (round ligament)

# 8 Pelvis and Perineum

1.
  - a. ilium
  - b. ischium
  - c. pubis
2. false pelvis
3. sacrotuberous ligament
4. sacrospinous ligament
5.
  - a. levator ani
  - b. coccygeus
6.
  - a. puborectalis
  - b. pubococcygeus
  - c. iliococcygeus
7. piriformis
8. puborectalis
9. broad ligament (mesometrium)
10. levator ani
11. internal iliac a (ant. div.)
12. internal iliac (ant. div.)
13. common iliac vein
14. pudendal nerve
15. S2 – S4
16. S2 – S4

17. hypogastric nerves
18. anterior
19. detrusor muscle
20. smooth muscle
21. striated (skeletal) muscle
22. pelvic splanchnic nerves
23.
  - a. ureteric orifices
  - b. urethral orifice
24.
  - a. inferior mesenteric artery
  - b. internal iliac artery
  - c. internal pudendal artery
25.
  - a. ductus deferens
  - b. seminal glands
26. bulbourethral (Cowper's) glands
27.
  - a. infundibulum
  - b. ampulla
  - c. isthmus
  - d. uterine part
28. broad ligament
29.
  - a. body
  - b. cervix
30.
  - a. inferior vena cava
  - b. left renal vein
31.
  - a. inferior vena cava
  - b. left renal vein
32.
  - a. perimetrium

- b. myometrium
  - c. endometrium
33. vesicouterine pouch
34. rectouterine pouch
35. a. urogenital triangle  
b. anal triangle
36. a. inferior fascia of the pelvic diaphragm  
b. perineal membrane
37. deep transverse perineus
38. a. bulbospongiosus  
b. ischiocavernosus  
c. superficial transverse perineus
39. obturator internus
40. smooth muscle
41. striated muscle
42. pectinate line
43. pectinate line
44. corpus spongiosum
45. corpus cavernosum
46. a. ilioinguinal nerve  
b. genital branch of the genitofemoral nerve  
c. superficial branch of the pudendal nerve  
d. perineal branch of the posterior femoral cutaneous nerve
47. internal pudendal artery
48. vestibular (Bartholin's) glands



- 49. broad ligament (mesosalpinx)
- 50.
  - a. inferior epigastric artery
  - b. deep circumflex iliac artery
- 51.
  - a. iliolumbar artery
  - b. lateral sacral artery
  - c. superior gluteal artery
  - d. obturator artery
  - e. internal pudendal artery
  - f. inferior gluteal artery
  - g. umbilical artery
  - h. inferior vesical artery
  - i. middle rectal artery
  - j. (female) uterine artery
  - k. (female) vaginal artery
- 52.
  - a. inferior mesenteric vein
  - b. internal iliac vein
  - c. internal iliac vein
- 53.
  - a. prostatic urethra
  - b. membranous urethra
  - c. spongy urethra
  - d. penile urethra
- 54. tunica albuginea
- 55. pampiniform plexus
- 56. ductus deferens
- 57.
  - a. sphincter urethrae
  - b. deep transverse perineus
- 58. pudendal nerve
- 59. greater vestibular glands
- 60. inferior rectal nerve

# 9 Head and Face

1.
  - a. occipital bone
  - b. parietal bone
2.
  - a. frontal bone
  - b. parietal bone
3.
  - a. zygomatic bone
  - b. temporal bone
4.
  - a. frontal bone
  - b. parietal bone
  - c. temporal bone
  - d. sphenoid bone
5. approximately 18 months
6. falx cerebri
7. tentorium cerebelli
8.
  - a. skin
  - b. dense connective tissue
  - c. epicranial aponeurosis
  - d. loose connective tissue
  - e. periosteum (pericranium)
9.
  - a. facial artery
  - b. lingual artery
  - c. superficial temporal artery
  - d. superior thyroid artery
  - e. maxillary artery
10. facial artery
11.
  - a. superior sagittal sinus
  - b. inferior sagittal sinus

- c. superior petrosal sinus
  - d. cavernous sinus
  - e. straight sinus
12. a. inferior petrosal sinus  
b. sigmoid sinus
13. vertebral artery
14. middle meningeal artery
15. a. right anterior cerebral artery  
b. left anterior cerebral artery
16. a. middle cerebral artery  
b. posterior cerebral artery
17. a. ophthalmic artery  
b. anterior choroidal artery  
c. posterior communicating artery  
d. middle cerebral artery  
e. anterior cerebral artery
18. facial nerve
19. a. temporalis  
b. masseter  
c. lateral pterygoid  
d. medial pterygoid
20. a. ophthalmic nerve  
b. maxillary nerve  
c. mandibular nerve
21. glossopharyngeal nerve  
a. otic ganglion
22. facial nerve  
a. submandibular ganglion
23. facial nerve  
a. pterygopalatine ganglion

- 24. facial nerve
- 25. trigeminal nerve
- 26. trigeminal nerve
  - a. ophthalmic nerve
    - 1) superior orbital fissure
  - b. maxillary nerve
    - 1) foramen rotundum
  - c. mandibular nerve
    - 1) foramen ovale
- 27. jugular foramen
- 28. stylopharyngeus
- 29. a. taste from posterior 1/3 of tongue
  - b. arterial pressure measured at the carotid sinus
- 30. jugular foramen
- 31. a. laryngeal muscles
  - b. upper third of the pharyngeal constrictors
- 32. slowing of heart rate
- 33. increased motility
- 34. a. blood gas monitoring at carotid body
  - b. taste from the epiglottis
- 35. a. foramen magnum
  - b. jugular foramen
- 36. a. sternocleidomastoid
  - b. trapezius
- 37. hypoglossal canal
- 38. genioglossus

- 39. facial nerve
- 40. internal auditory (acoustic) meatus
- 41. stylomastoid foramen
- 42.
  - a. temporal branch
  - b. zygomatic branch
  - c. buccal branch
  - d. marginal mandibular branch
  - e. cervical branch
- 43.
  - a. greater superficial petrosal nerve
  - b. deep petrosal nerve
- 44. facial nerve (nervus intermedius)
- 45. facial nerve (nervus intermedius)
- 46. glossopharyngeal nerve
- 47.
  - a. trigeminal
  - b. vagus
- 48.
  - a. tensor tympani
  - b. tensor veli palatini
  - c. anterior belly of the digastric
  - d. mylohyoid
- 49.
  - a. posterior belly of the digastric
  - b. stapedius
  - c. stylohyoid
- 50. superior orbital fissure
- 51. foramen rotundum
- 52. foramen ovale
- 53. optic foramen

- 54. a. facial nerve
  - b. vestibular nerve
  - c. cochlear nerve
- 55. inferior alveolar nerve
- 56. ciliary ganglion
- 57. pterygopalatine ganglion
- 58. otic ganglion
- 59. submandibular ganglion
- 60. maxillary nerve
- 61. internal carotid artery
- 62. abducens nerve
- 63. nasopalatine nerve
- 64. maxillary artery
- 65. facial nerve
- 66. glossopharyngeal nerve
- 67. glossopharyngeal nerve
- 68. otic ganglion
- 69. mental nerve
- 70. frontal bone
- 71. ethmoid bone
- 72. sphenoid bone
- 73. temporal bone

- 74.
  - a. sphenoid bone
  - b. occipital bone
- 75. emissary veins
- 76. diploic veins
- 77.
  - a. great vein of Galen
  - b. inferior sagittal sinus
- 78. chorda tympani

# 10 Mouth and Pharynx

1.
  - a. masseter
  - b. temporalis
2. mylohyoid
3. palatoglossus
  - a. vagus nerve
4. palatopharyngeus
  - a. vagus nerve
5. palatoglossus
6. palatopharyngeus
7. glossopharyngeal nerve
8.
  - a. levator veli palatine
  - b. tensor veli palatine
9. vagus nerve
10. hypoglossal nerve
11. hypoglossal nerve
12. palatoglossus
  - a. vagus nerve
13. trigeminal nerve
14. glossopharyngeal nerve
15. glossopharyngeal nerve
16. glossopharyngeal nerve



17. facial nerve
18. glossopharyngeal nerve
19. maxillary nerve (trigeminal V2)
20. mandibular nerve (trigeminal V3)
21. greater palatine nerve
22. lesser palatine nerve
23. foramen cecum
24.
  - a. vagus nerve
  - b. vagus nerve
  - c. glossopharyngeal nerve
25. palatine tonsil
26. facial nerve
27.
  - a. pterygomandibular raphe
  - b. hyoid bone
  - c. thyroid cartilage
28.
  - a. stylopharyngeus
  - b. palatopharyngeus
  - c. salpingopharyngeus
29. eustachian (auditory or pharyngotympanic) tube
30. retropharyngeal space

# 11 Neck and Larynx

1.
  - a. investing fascia
  - b. pretracheal fascia
  - c. prevertebral fascia
  - d. carotid sheath
  
2.
  - a. sternocleidomastoid
  - b. trapezius
  
3.
  - a. infrahyoid muscles
  - b. thyroid gland
  - c. trachea
  - d. esophagus
  
4.
  - a. carotid arteries
  - b. internal jugular vein
  - c. vagus nerve
  
5.
  - a. midline of neck
  - b. anterior border of sternocleidomastoid
  - c. inferior border of mandible
  
6.
  - a. anterior border of sternocleidomastoid
  - b. posterior belly of digastric
  - c. superior belly of omohyoid
  
7.
  - a. posterior belly of digastric
  - b. anterior belly of digastric
  - c. inferior border of mandible
  
8.
  - a. anterior belly of digastric
  - b. hyoid bone
  - c. midline beneath mandible
  
9.
  - a. superior belly of omohyoid
  - b. anterior border of sternocleidomastoid
  - c. sternohyoid

10.
  - a. anterior border of trapezius
  - b. posterior border of sternocleidomastoid
  - c. superior border of clavicle
  
11.
  - a. sternohyoid
  - b. thyrohyoid
  - c. sternothyroid
  - d. omohyoid
  
12.
  - a. digastric
  - b. stylohyoid
  - c. mylohyoid
  - d. geniohyoid
  
13. posterior cricoarytenoid
  
14. internal laryngeal nerve (branch of superior laryngeal)
  
15.
  - a. lateral cricoarytenoid
  - b. transverse arytenoid
  
16. internal laryngeal nerve
  
17. cricothyroid
  
18. external laryngeal nerve
  
19. internal laryngeal nerve
  
20.
  - a. anterior scalene
  - b. middle scalene
  
21. posterior
  
22. anterior
  
23. lateral border of first rib
  
24.
  - a. vertebral artery
  - b. thyrocervical trunk (artery)
  - c. internal thoracic artery

- d. costocervical trunk (artery)
  - e. dorsal scapular artery
25. external carotid artery
26. common carotid artery
27. a. superficial temporal vein  
b. maxillary vein
28. a. retromandibular vein  
b. posterior auricular vein
29. a. internal jugular vein  
b. subclavian vein
30. C3, C4, C5
31. C1, C2, C3
32. C4
33. C1 - C4
34. C5 and C6
35. C7, C8, (T1)
36. a. ascending pharyngeal artery  
b. occipital artery  
c. posterior auricular artery  
d. superior thyroid artery  
e. lingual artery  
f. facial artery
37. a. maxillary artery  
b. superficial temporal artery
38. a. inferior thyroid artery  
b. transverse cervical artery  
c. suprascapular artery

- 39.
  - a. lesser occipital nerve
  - b. great auricular nerve
  - c. transverse cervical nerve
  - d. supraclavicular nerve(s)
  
- 40. anterior scalene
- 41.
  - a. internal jugular vein
  - b. internal jugular vein
  - c. left brachiocephalic vein
  
- 42.
  - a. occipital triangle
  - b. omoclavicular triangle
  
- 43.
  - a. anterior border of trapezius
  - b. posterior border of sternocleidomastoid
  - c. inferior belly of omohyoid
  
- 44.
  - a. posterior border of sternocleidomastoid
  - b. inferior belly of omohyoid
  - c. superior border of the clavicle
  
- 45. sternocleidomastoid
  
- 46. anterior scalene
  
- 47. spinal accessory nerve (XI)
  
- 48. greater occipital nerve
  
- 49.
  - a. chemoreceptors
  - b. baroreceptors
  
- 50.
  - a. brachiocephalic artery (trunk)
  - b. left vertebral artery
  - c. left subclavian artery
  
- 51. phrenic nerve
  
- 52.
  - a. right subclavian artery
  - b. arch of the aorta or ligamentum arteriosum

- 53.
  - a. thyrocervical trunk
  - b. external carotid artery
  
- 54.
  - a. internal jugular vein
  - b. internal jugular vein
  - c. brachiocephalic vein
  
- 55. C4
- 56. cricothyroid membrane
  
- 57. thyrohyoid membrane
  
- 58. cricothyroid muscle
  
- 59.
  - a. internal laryngeal nerve (branch of the superior laryngeal nerve)
  - b. superior thyroid artery
  
- 60.
  - a. internal laryngeal nerve
  - b. inferior laryngeal nerve
  
- 61. thyrohyoid membrane
  
- 62. arytenoid cartilage
  
- 63. posterior atlantooccipital membrane
  
- 64. facial nerve
  
- 65. 2nd, 3rd and 4th
  
- 66.
  - a. sigmoid sinus
  - b. inferior petrosal sinus
  - c. lingual vein
  - d. pharyngeal veins
  - e. facial vein
  - f. superior thyroid vein
  - g. middle thyroid vein
  
- 67.
  - a. meningeal branches
  - b. auricular branch

- 68. inferior pharyngeal constrictor
- 69. internal laryngeal nerve
- 70. facial artery
- 71. omoclavicular triangle (of the posterior triangle)
- 72. occipital triangle (of the posterior triangle)
- 73. roots of the brachial plexus
- 74. middle and inferior cervical ganglia (stellate)
- 75.
  - a. thyroid cartilage
  - b. cricoid cartilage
  - c. arytenoid cartilage
  - d. corniculate cartilage
  - e. cuneiform cartilage
  - f. epiglottic cartilage
- 76.
  - a. vestibular folds
  - b. vocal fold
- 77. vocalis
- 78. C7
- 79. great auricular nerve
- 80.
  - a. lesser occipital nerve
  - b. spinal accessory nerve
  - c. supraclavicular nerve
  - d. transverse cervical nerve
  - e. great auricular nerve
- 81. dorsal scapular nerve
- 82.
  - a. transverse cervical artery
  - b. suprascapular artery

83. anterior

84. sternothyroid muscle



# 12 Orbit

1.
  - a. optic canal
  - b. superior orbital fissure
  - c. inferior orbital fissure
2.
  - a. optic nerve
  - b. ophthalmic artery
3.
  - a. frontal nerve
  - b. lacrimal nerve
  - c. nasociliary nerve
  - d. oculomotor nerve
  - e. trochlear nerve
  - f. abducens nerve
  - g. superior ophthalmic vein
  - h. inferior ophthalmic vein
4.
  - a. oculomotor nerve (superior branch)
  - b. oculomotor nerve (inferior branch)
  - c. nasociliary nerve
  - d. abducens nerve
5. conjunctiva
6.
  - a. levator palpebrae superioris
  - b. superior tarsal muscle (Mueller's muscle)
7.
  - a. tarsal glands
  - b. ciliary glands
8. anterior in the supero-lateral margin
9. below the inferior nasal concha
10. facial nerve
11. inferior oblique

12. oculomotor
13. superior cervical ganglion
14.
  - a. frontal nerve
  - b. nasociliary nerve
  - c. lacrimal nerve
15. maxillary nerve
16. nasociliary nerve
17. nasociliary nerve
18. ophthalmic artery
19. cavernous sinus

# 13 Eye

1.
  - a. sclera (fibrous)
  - b. choroid (vascular)
  - c. retina (neural)
2. long ciliary > nasociliary > trigeminal
3. iris
4. aqueous humor
5. aqueous humor
6.
  - a. pupillary constrictor                      parasympathetic
  - b. pupillary dilator                              sympathetic
7. suspensory ligament of the lens (zonular fibers of Zinn)
8. accommodation of the lens
9. Edinger-Westphal nucleus                      ciliary ganglion
10. Edinger-Westphal nucleus                      ciliary ganglion
11. intermediolateral nucleus                      superior cervical ganglion
12. ciliary body
13. canal of Schlemm (scleral venous sinus)
14. lateral margin of the anterior chamber
15. point of exit of retinal ganglion cell axons from the retina
16. center of the optic disc
17. retinal region of high visual acuity

18. center of macula lutea – area of highest visual acuity
19. optic disc
20.
  - a. rods
  - b. cones
21. cone
22. ophthalmic artery
23.
  - a. cavernous sinus (posteriorly)
  - b. pterygoid sinus (inferiorly)
  - c. angular vein (anteriorly)

# 14 Ear

1.
  - a. great auricular nerve
  - b. auriculotemporal nerve
  
2. 

malleus	1st arch
incus	2nd arch
stapes	3rd arch
  
3. malleus
  
4. stapes
  
5. tensor tympani
  - a. trigeminal
  
6. stapedius
  - a. facial
  
7. cochlear (auditory)
  
8. internal auditory meatus
  
9. semicircular canals
  
10. utricle and saccule (otolithic organs)
  
11. perilymph
  
12. perilymph
  
13. endolymph
  
14. endolymph
  
15. utricle and saccule (otolithic organs)
  
16. spiral ganglion

17. vestibular (Scarpa's) ganglion
18. anterior-inferior quadrant
19.
  - a. chorda tympani
  - b. lesser superficial petrosal nerve
20. 2nd branchial arch
21. 1st branchial arch

# About the Authors

**Michael F. Nolan** is professor of Basic Science Education at the Virginia Tech Carilion School of Medicine in Roanoke. He received his Physical Therapy training at Marquette University and his PhD in Human Anatomy from the Medical College of Wisconsin. Nolan spent the first 34 years of his career teaching gross anatomy and neuroanatomy to medical students and resident physicians at the University of South Florida. He has received more than 20 awards for excellence in teaching including the Master Teacher Award in 2014 from the International Association of Medical Science Educators and the John M. Thompson Outstanding Teacher Award in Neurosurgery in 2006. He has published over 40 peer-reviewed articles and book chapters as well as four textbooks in human gross anatomy and neuroanatomy.

**John P. McNamara** is the Director of Anatomy and Assistant Professor of Basic Science Education at the Virginia Tech Carilion School of Medicine in Roanoke. His doctoral training is in chiropractic from Life University (Marietta, GA) with undergraduate (Lock Haven University of Pennsylvania) and graduate (Shippensburg University of Pennsylvania) degrees. He is also ABD from Virginia Tech in Educational Leadership and Policy Studies. For nearly the past 30 years, McNamara has maintained a private practice in Salem, VA, and taught full-time anatomy and physiology, gross anatomy, neuroanatomy, and pathophysiology at the College of Health Sciences (Jefferson College) in Roanoke. From 2013 to 2017 he taught the gross anatomy course for the Doctor of Physical Therapy program at Radford University in Roanoke. He is licensed to practice as a Doctor of Chiropractic in both Virginia and Pennsylvania, and he is certified as an Emergency Medical Technician in Virginia.













